

**« Mon pire cauchemar »
Quand il y a le feu au lac !**



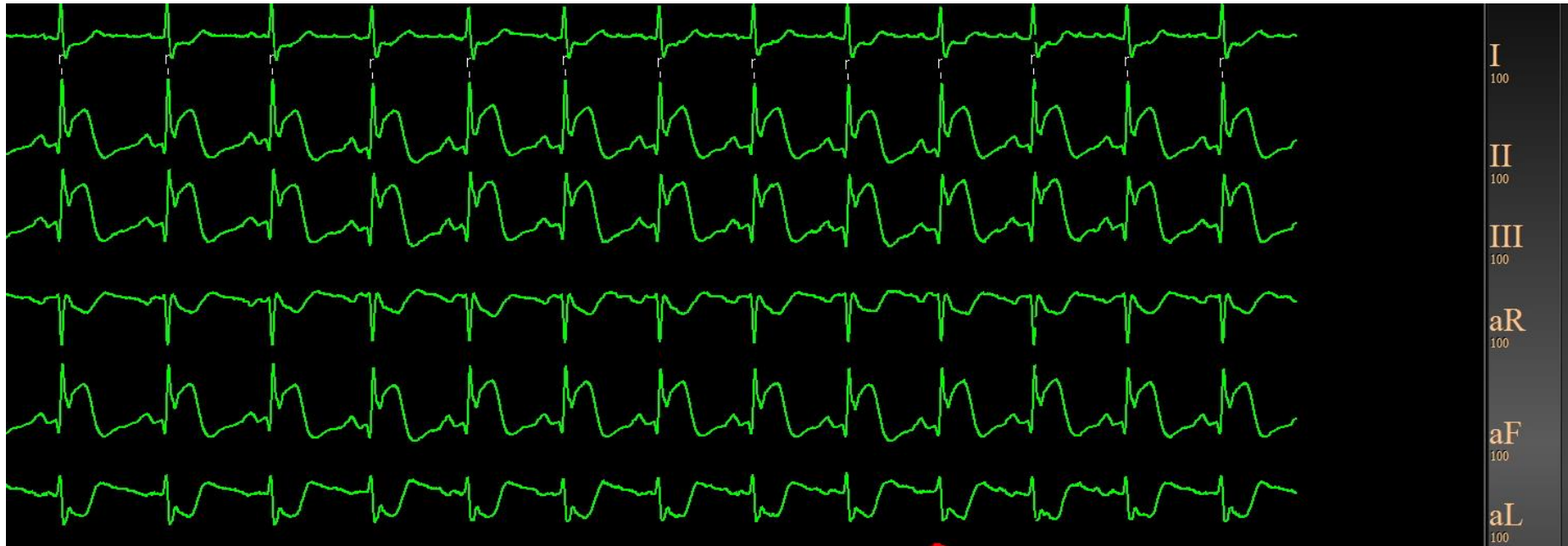GRCI 2018 Julien Adjedj

DÉCLARATION DE LIENS D'INTÉRÊT AVEC LA PRÉSENTATION

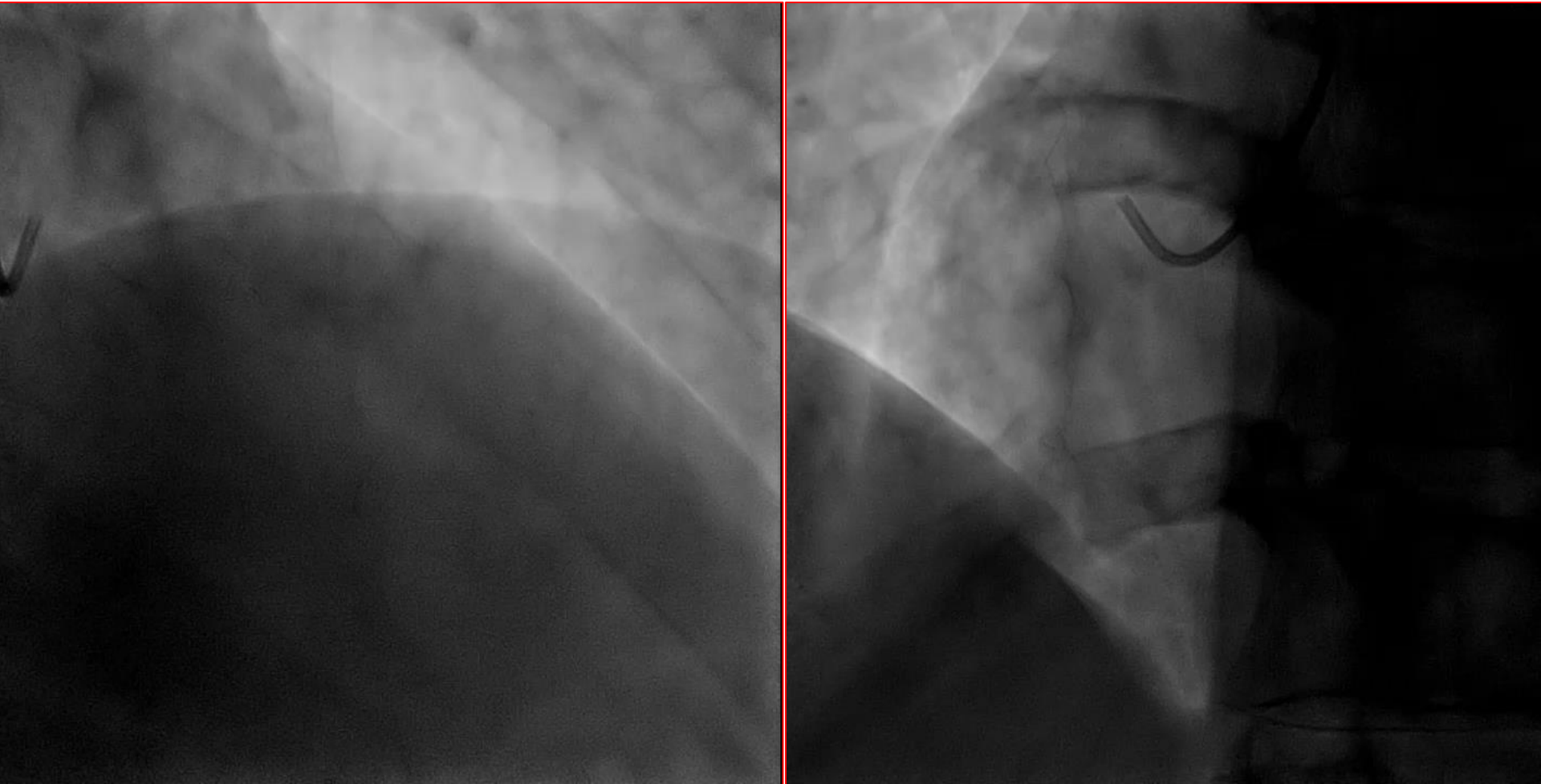
Julien Adjedj, Lausanne

Je n'ai pas de lien d'intérêt à déclarer

Patient de 44 ans avec STEMI inferieur

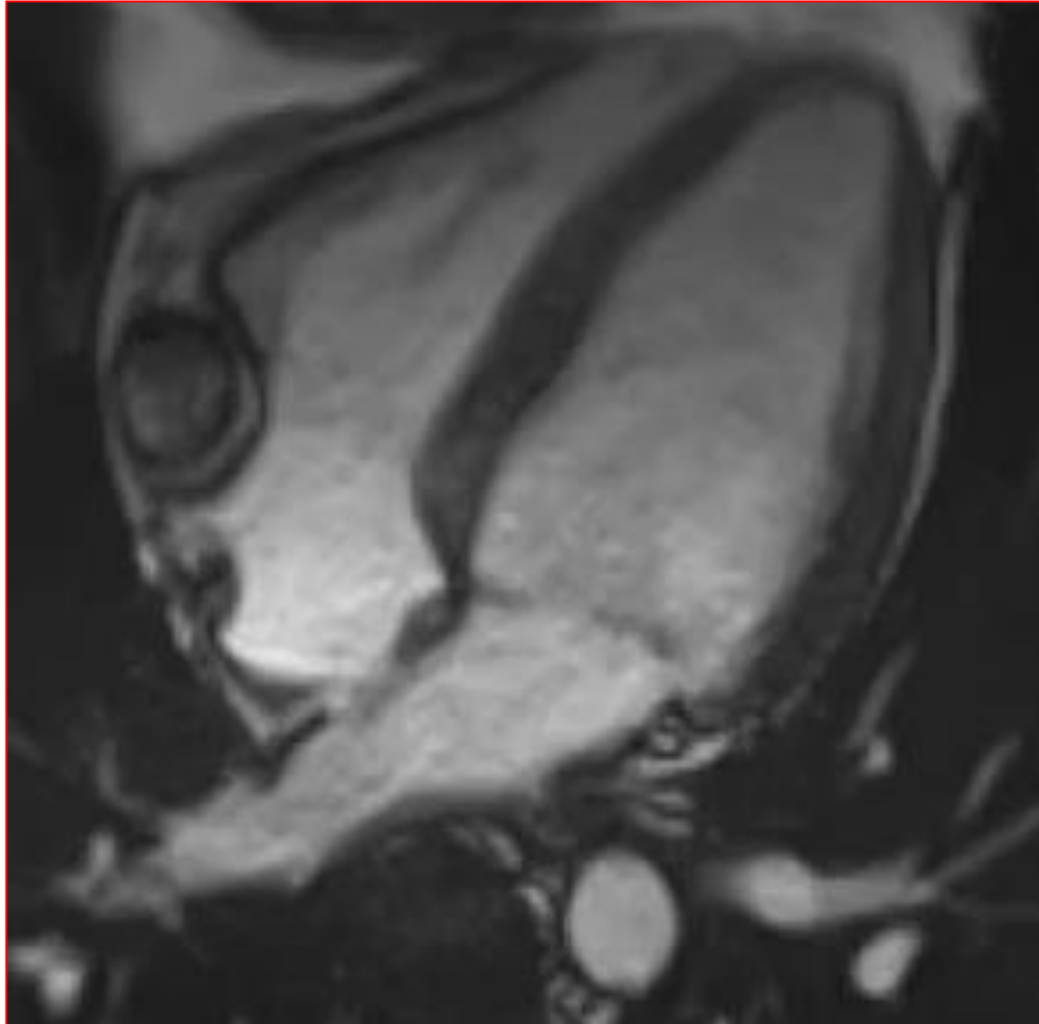


ATCD en 2015 de STEMI



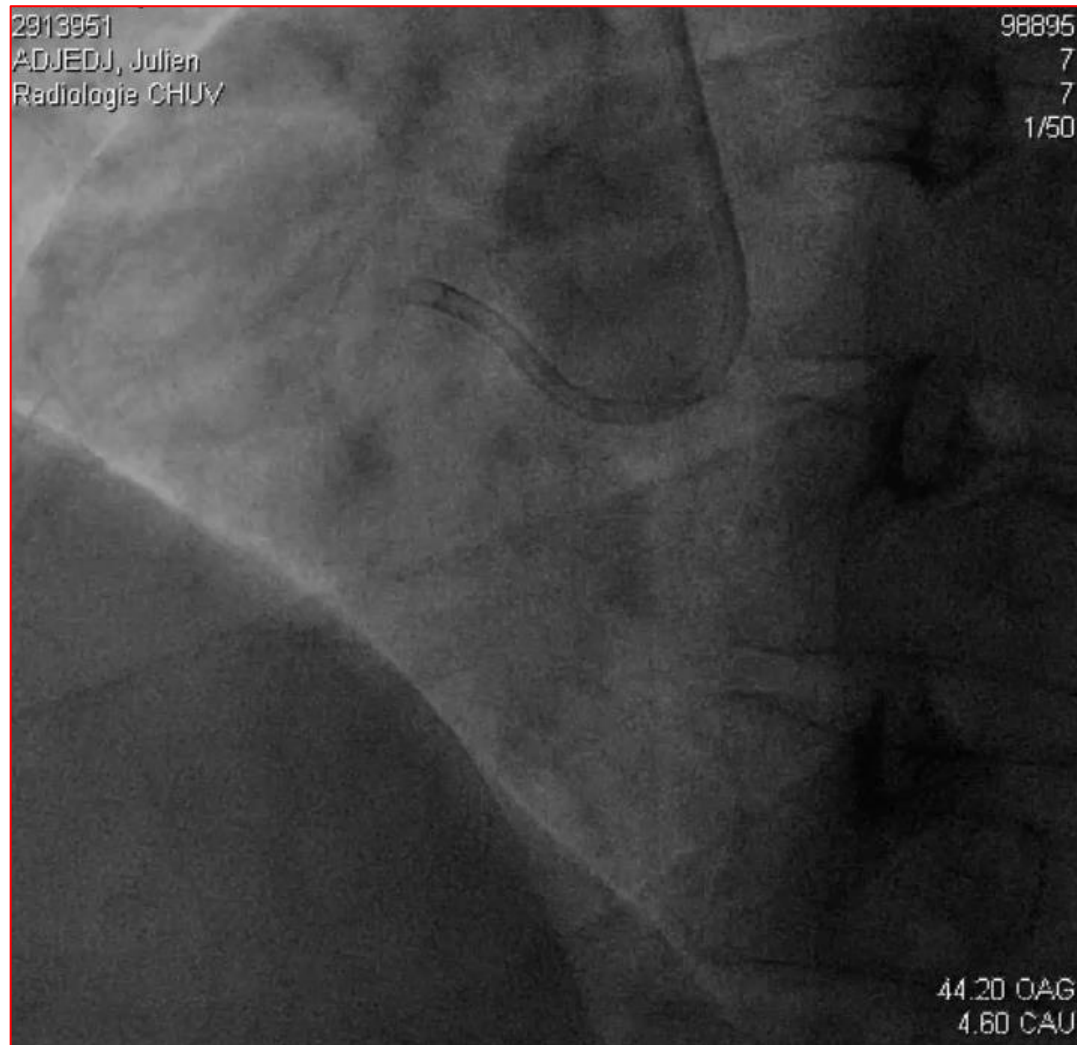
Traitement médical sous AVK-Plavix puis AOD seul à 1 an

ATCD en 2015 de STEMI



Traitement médical sous AVK-Plavix puis Xarelto seul à 1 an

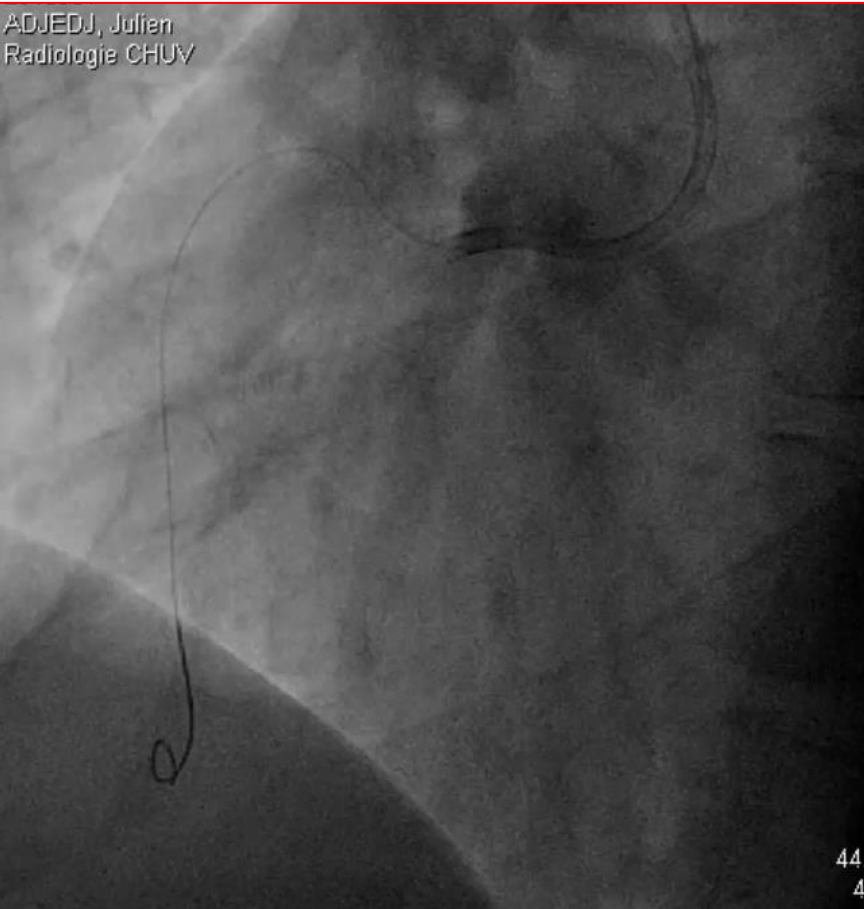
Materiel



- Sous Xarelto
- Chargé en aspirine, brilique et HNF
- Intro Radial slender 6F pour 7F
- AL 0.75 en 7 F

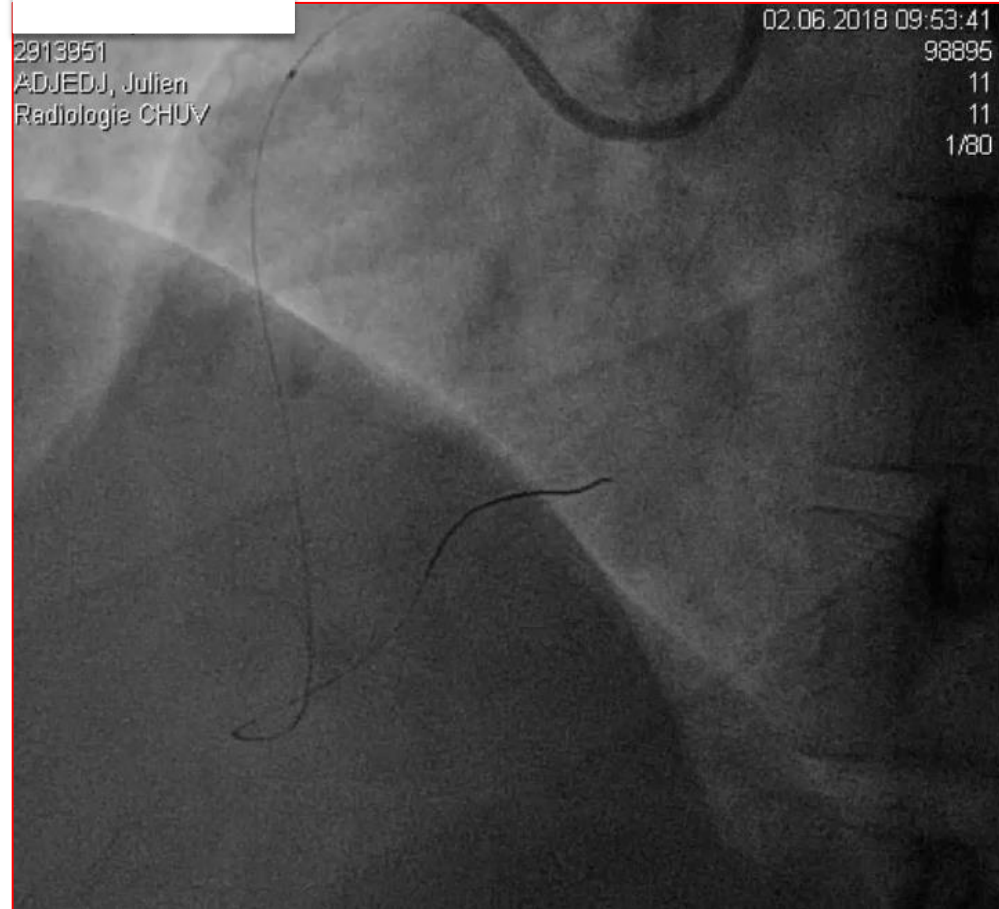
Voir la distalité

ADJEDJ, Julien
Radiologie CHUV



44
4

2913851
ADJEDJ, Julien
Radiologie CHUV



02.06.2018 09:53:41

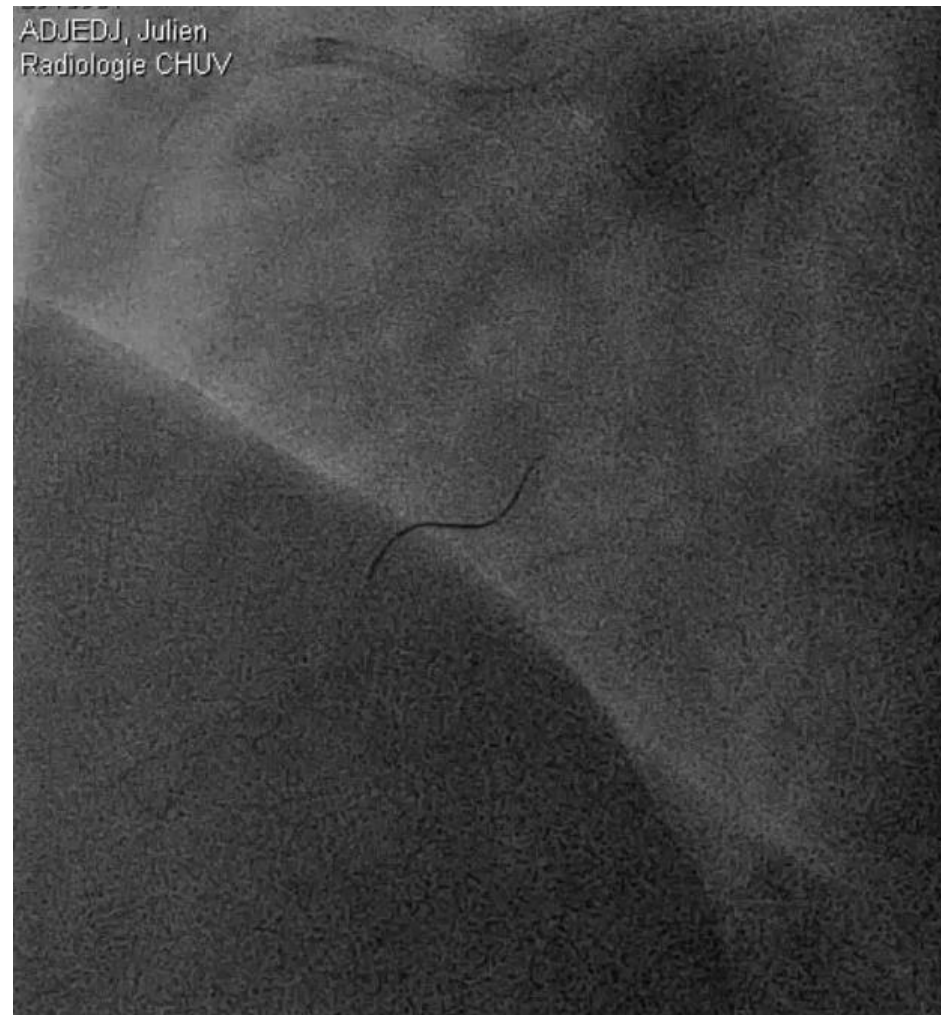
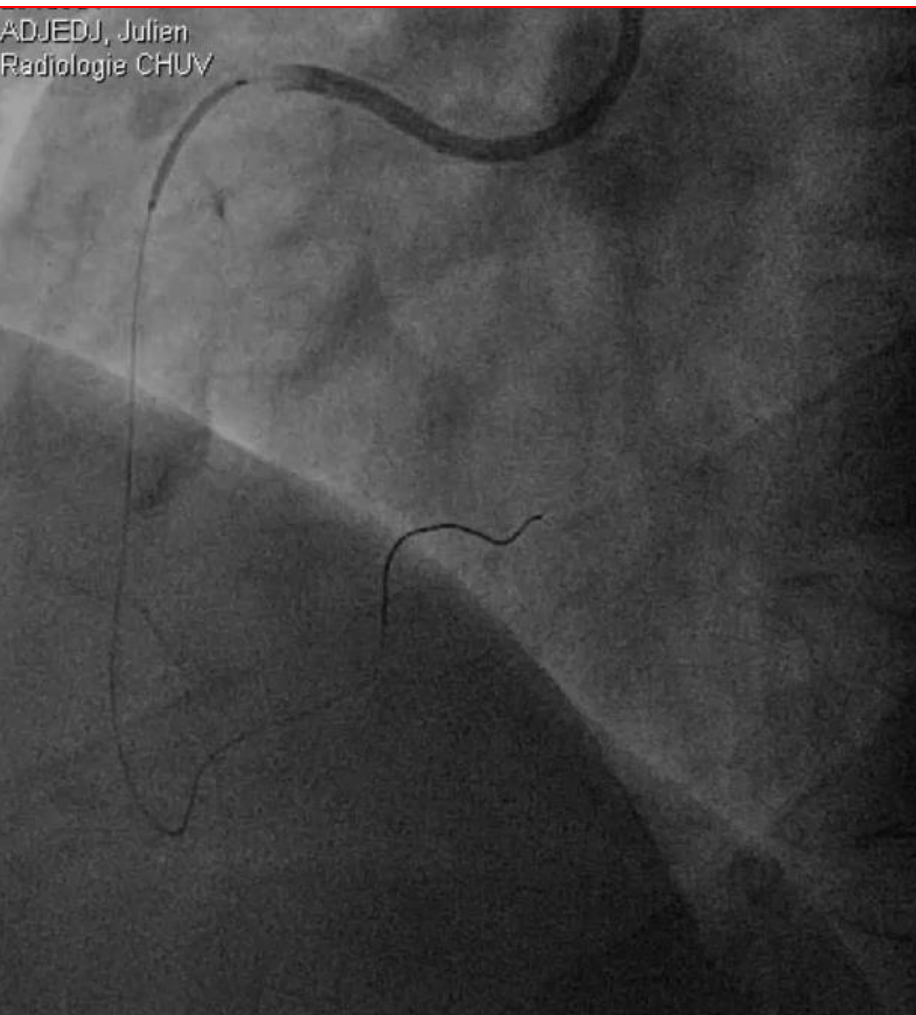
98896

11

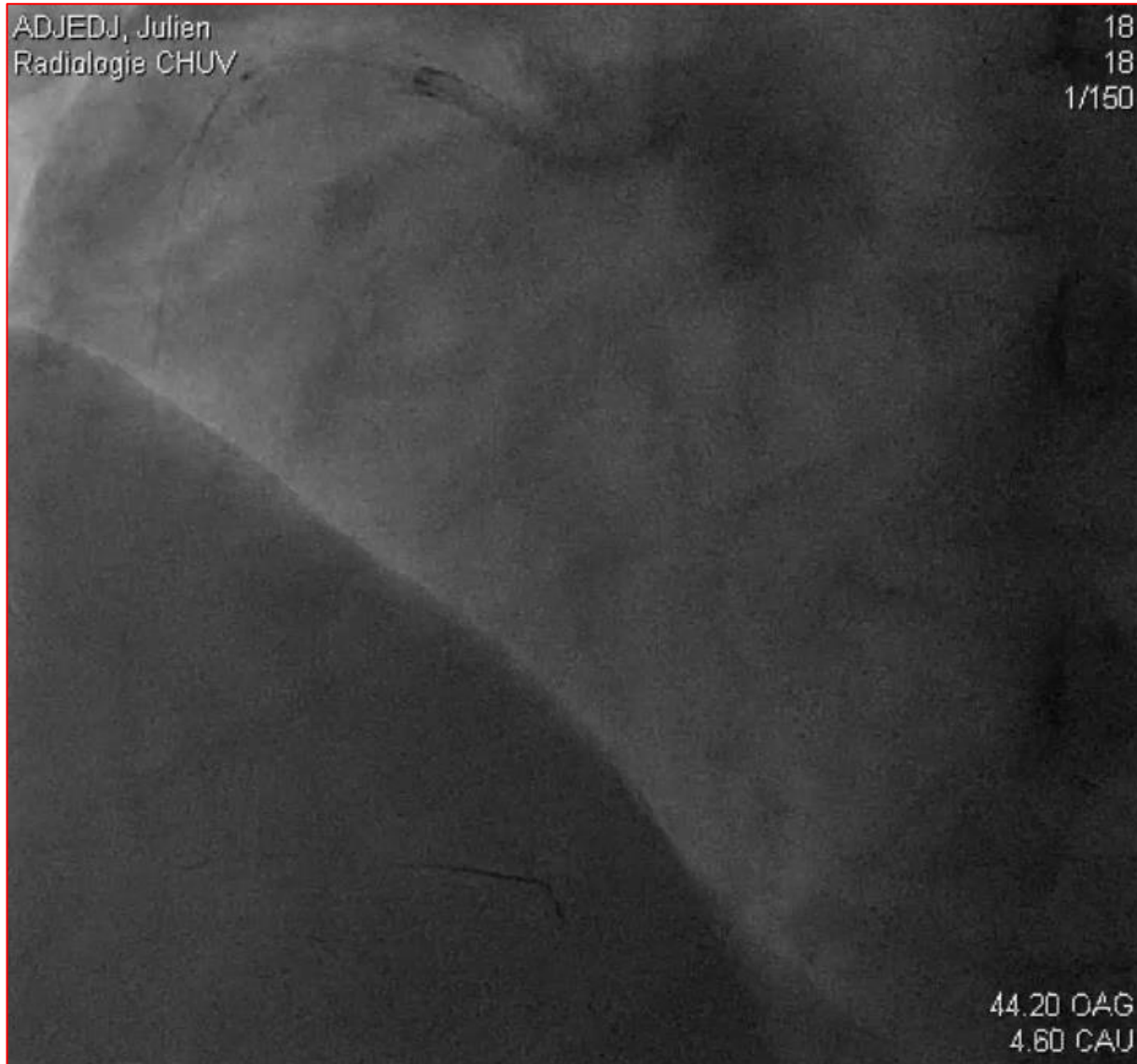11

1/30

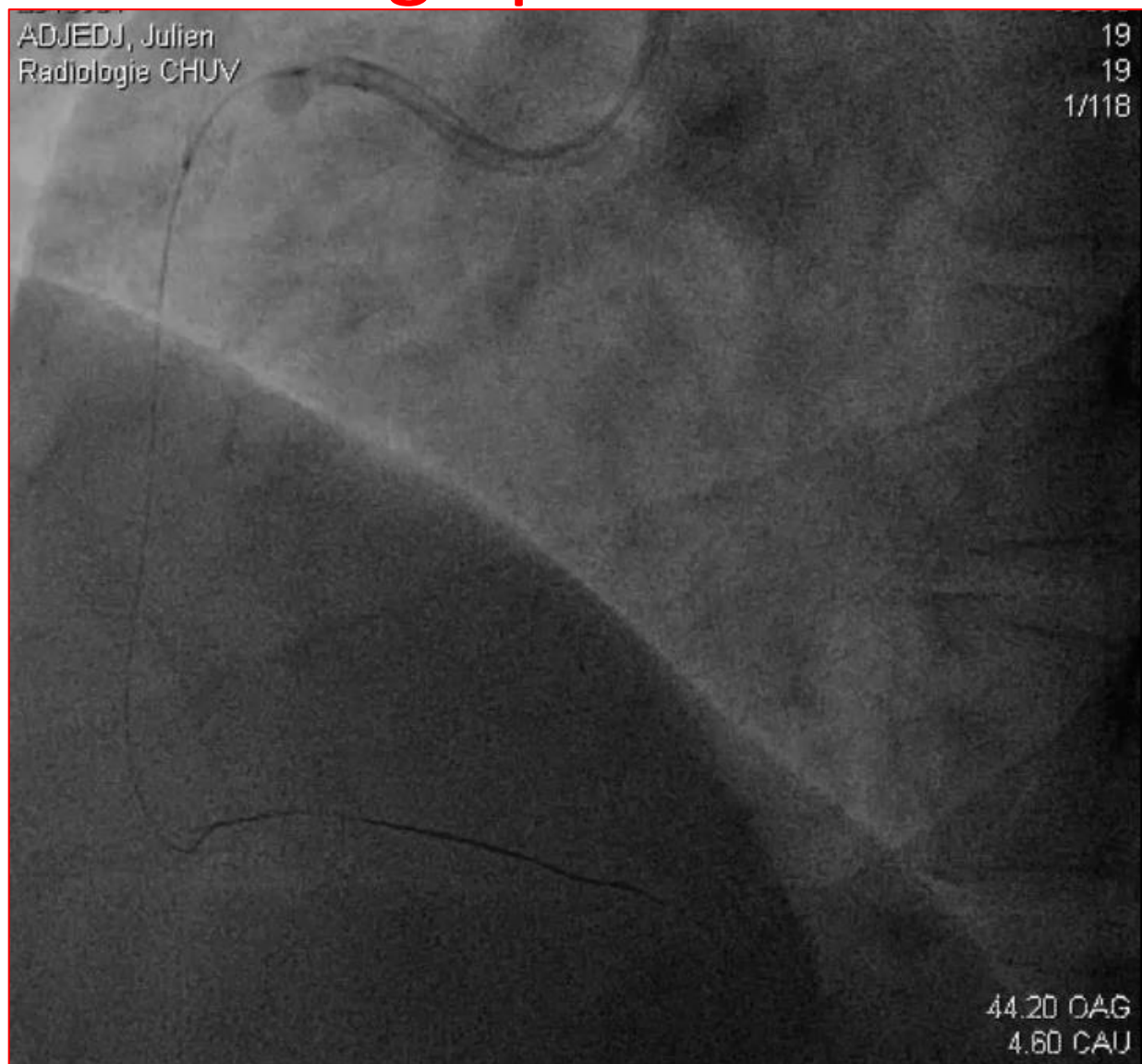
Angioplastie DES 3.5 x 15 mm...



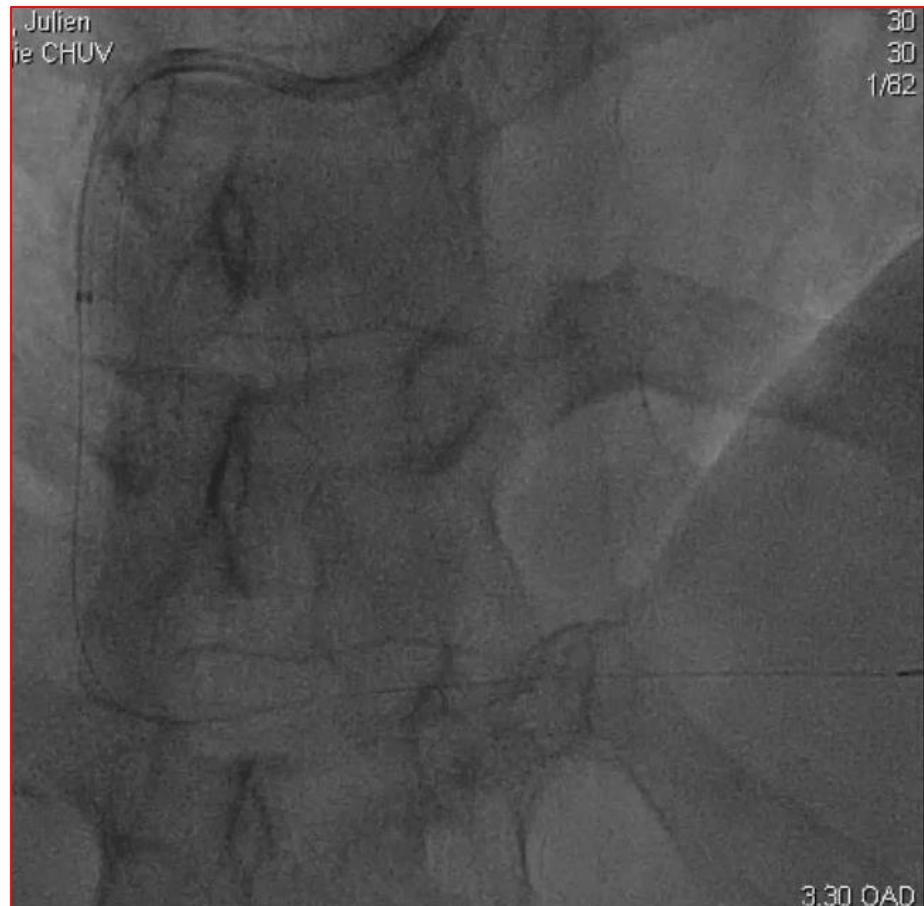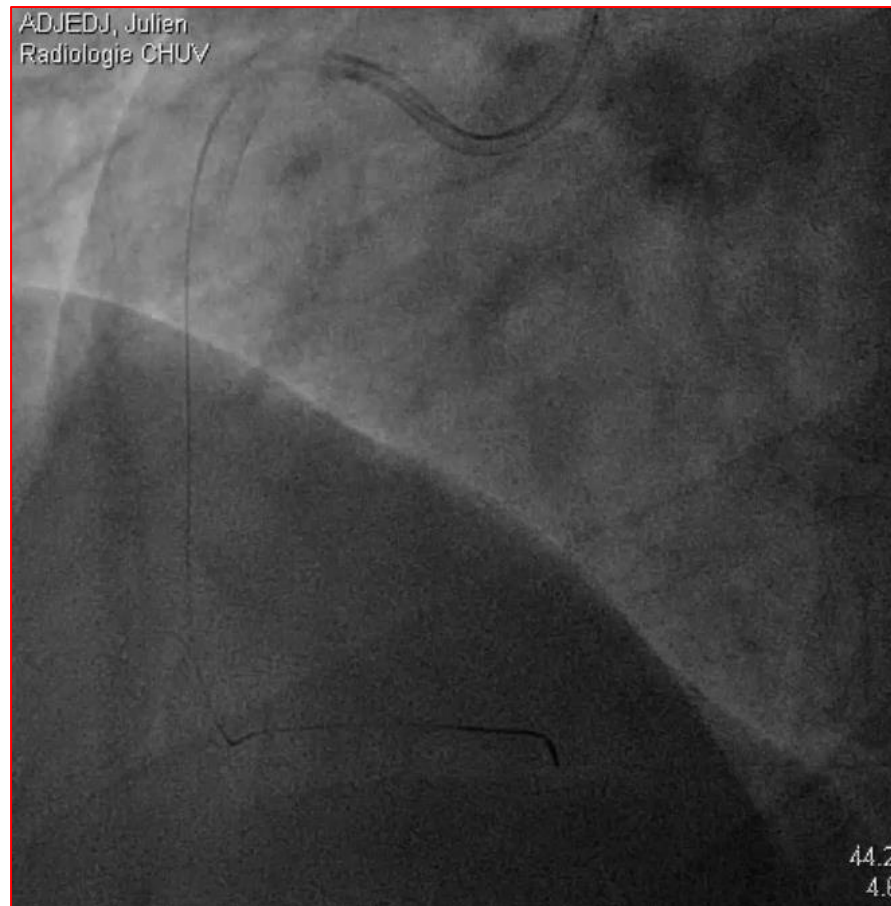
Dilatation de la distalité



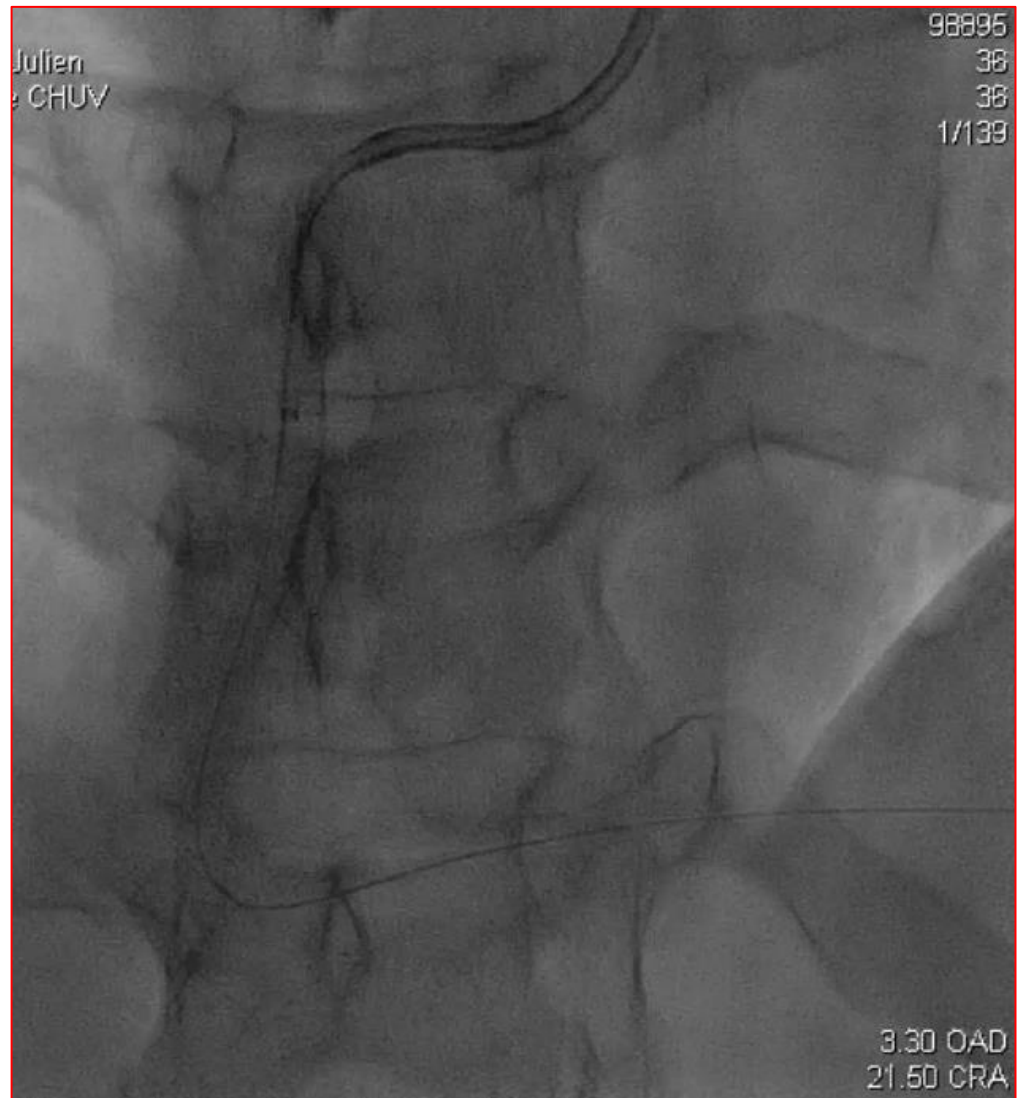
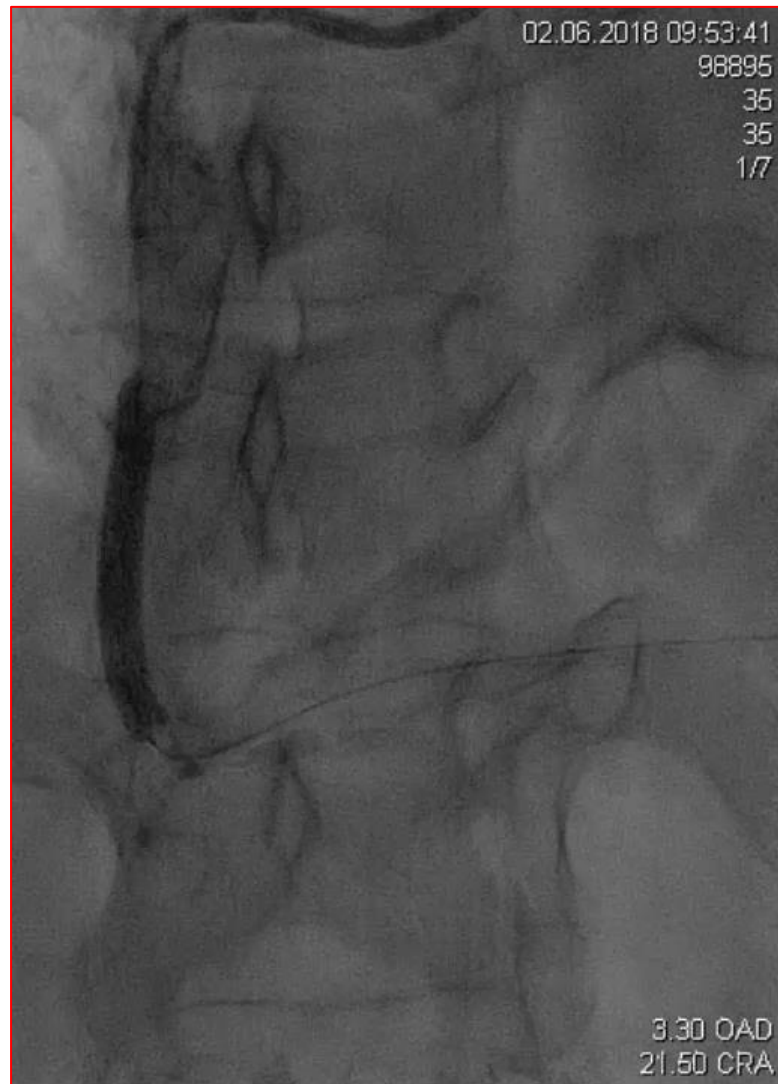Recapture et angioplastie DES 4.0 x 15mm



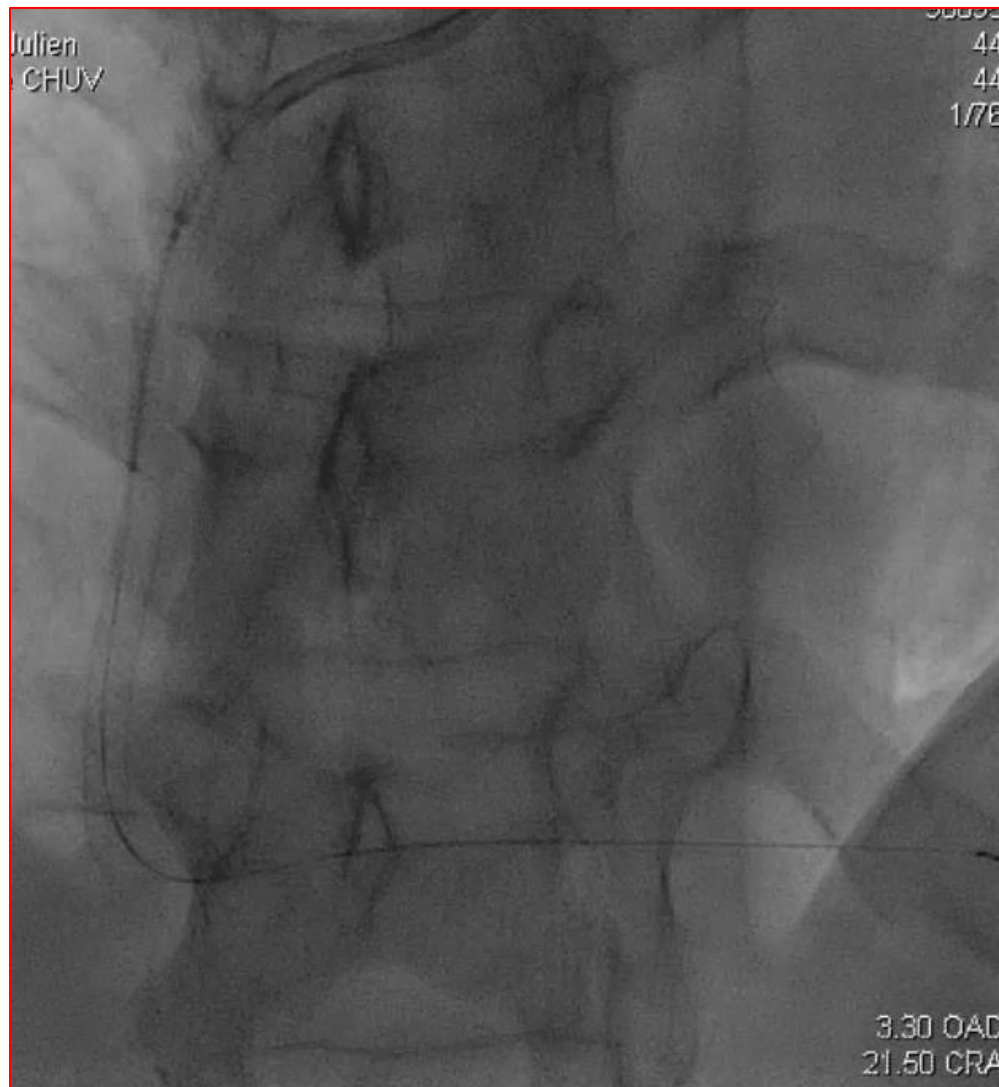
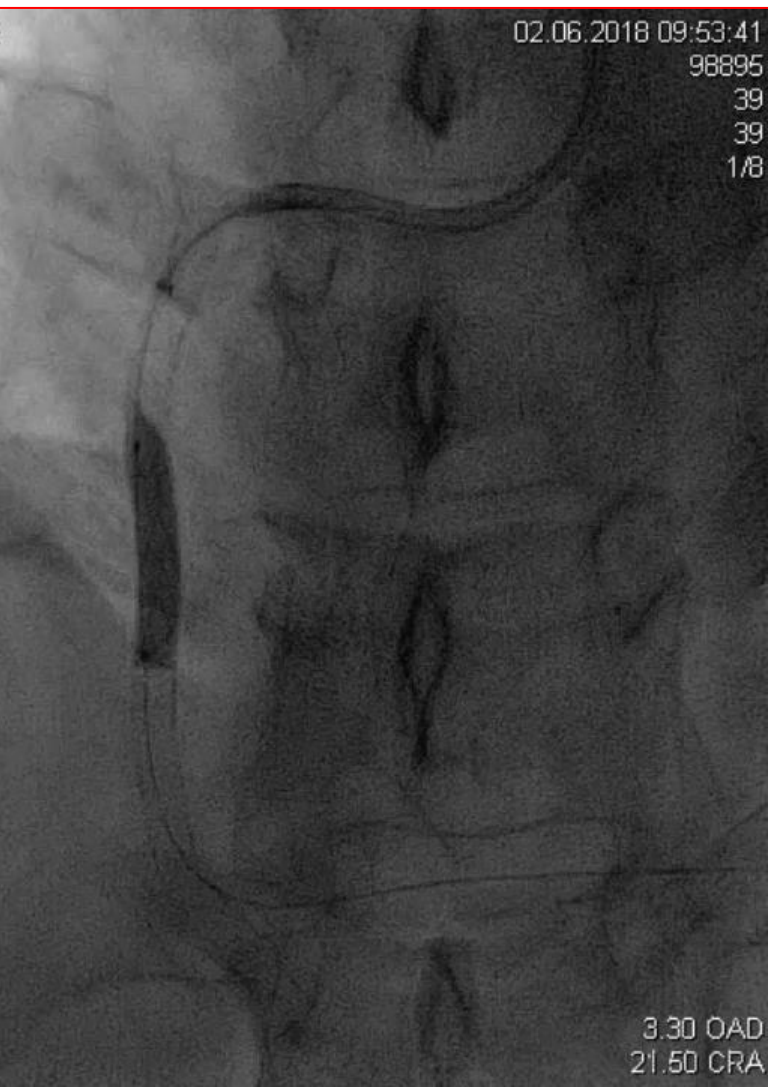
Mother and child 6F



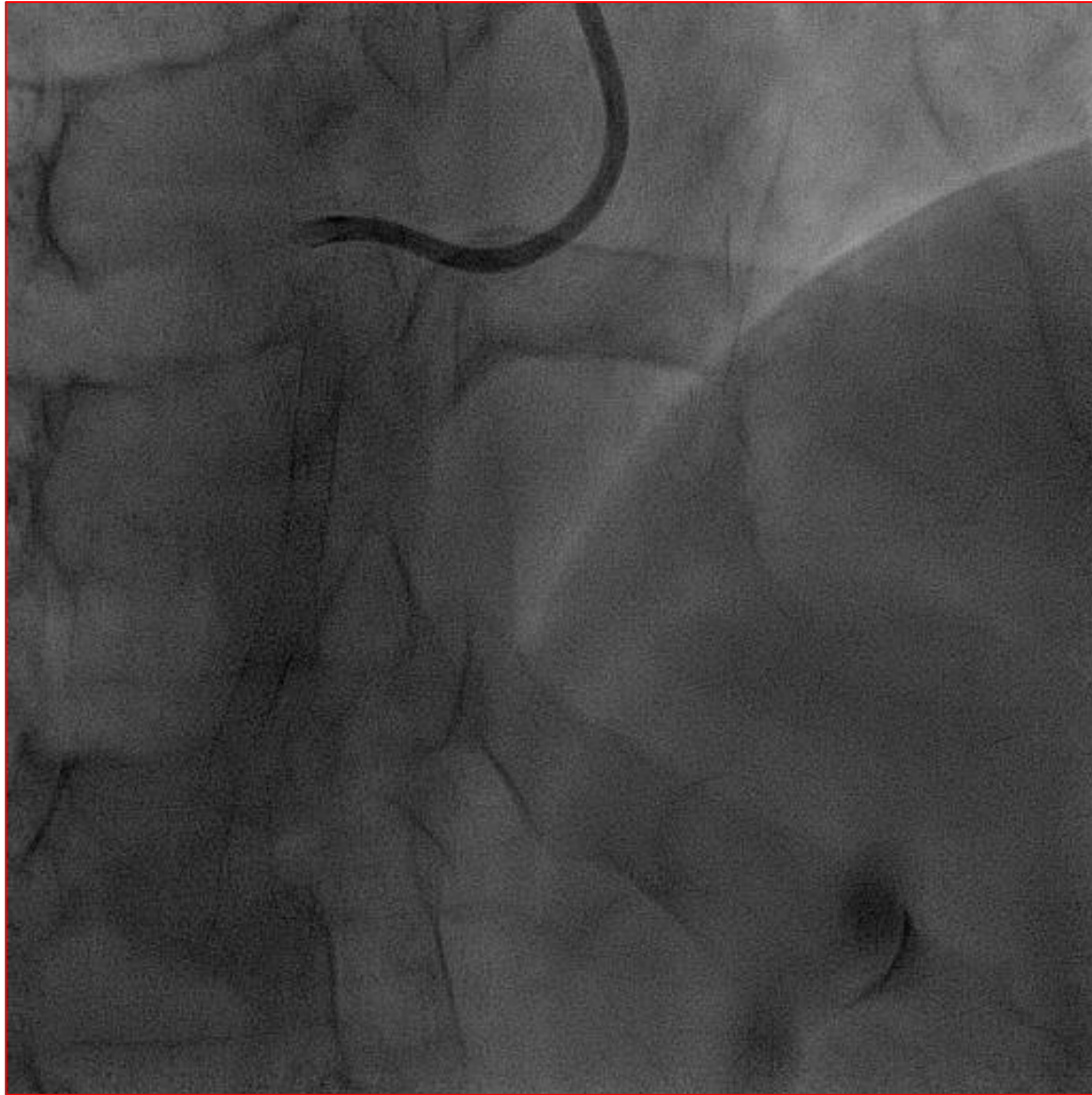
DES 3.5 x 38



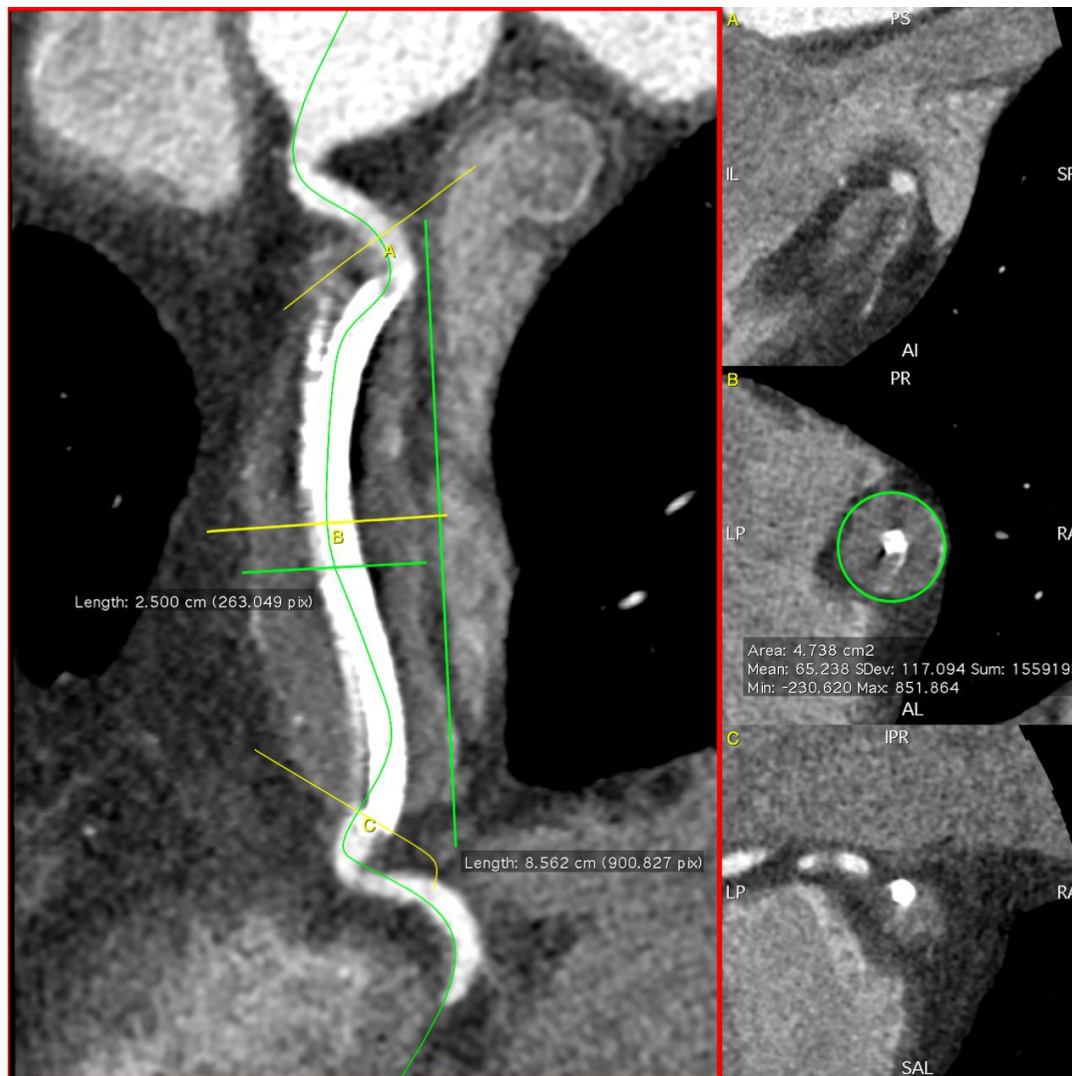
Cover stents 3.5 x 20 PK papyrus



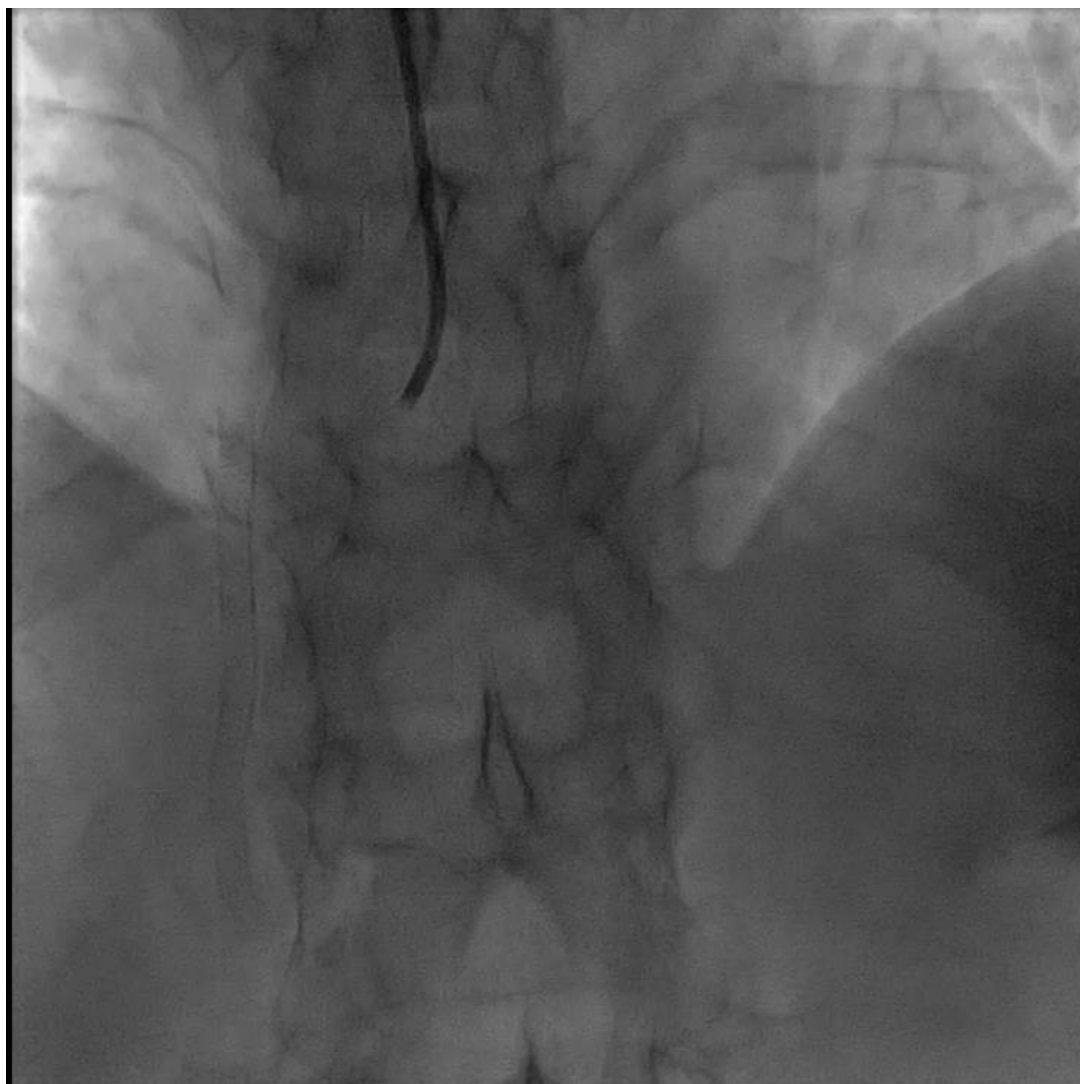
On s'arrête là



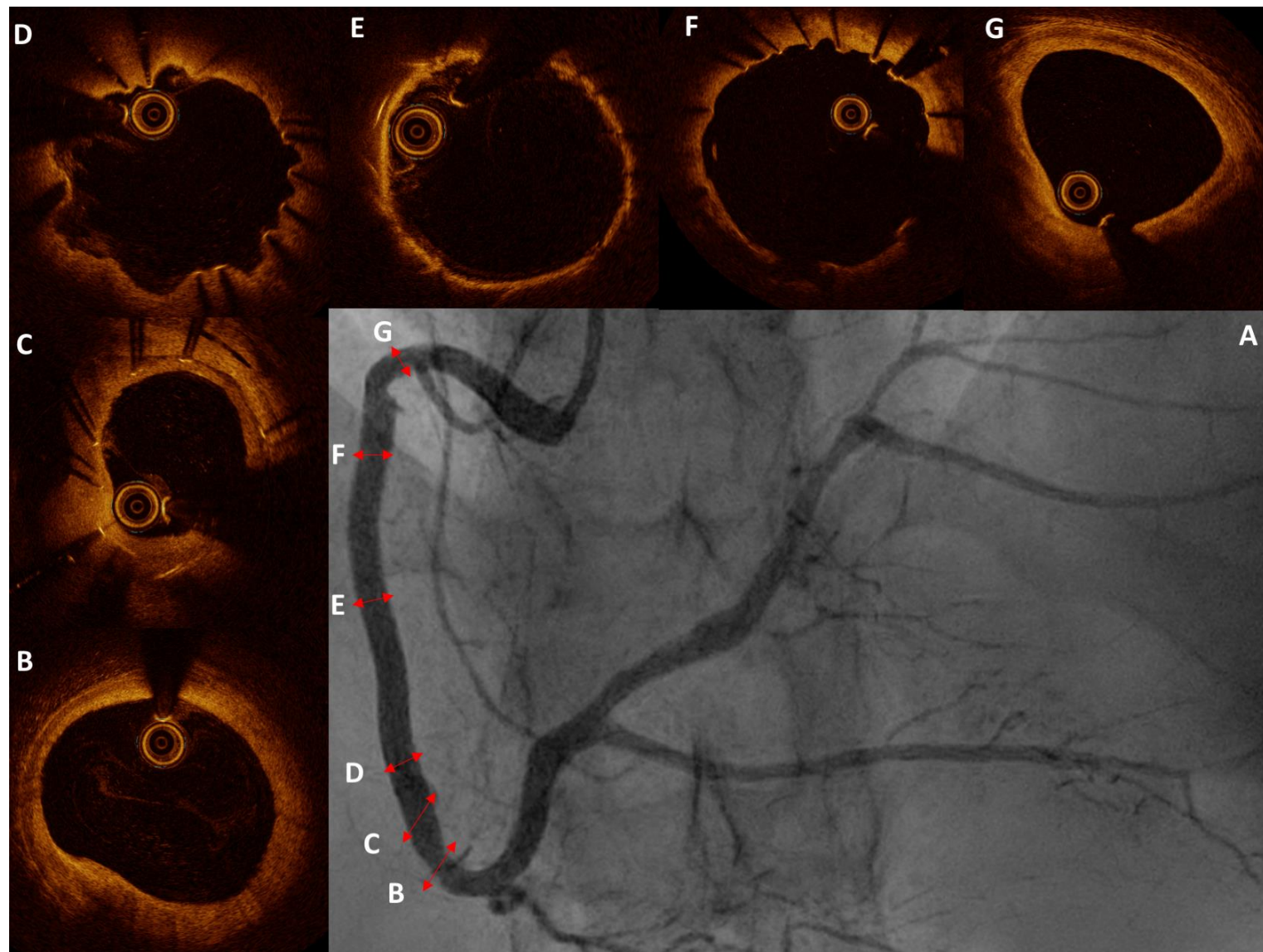
Suivi à 3 mois



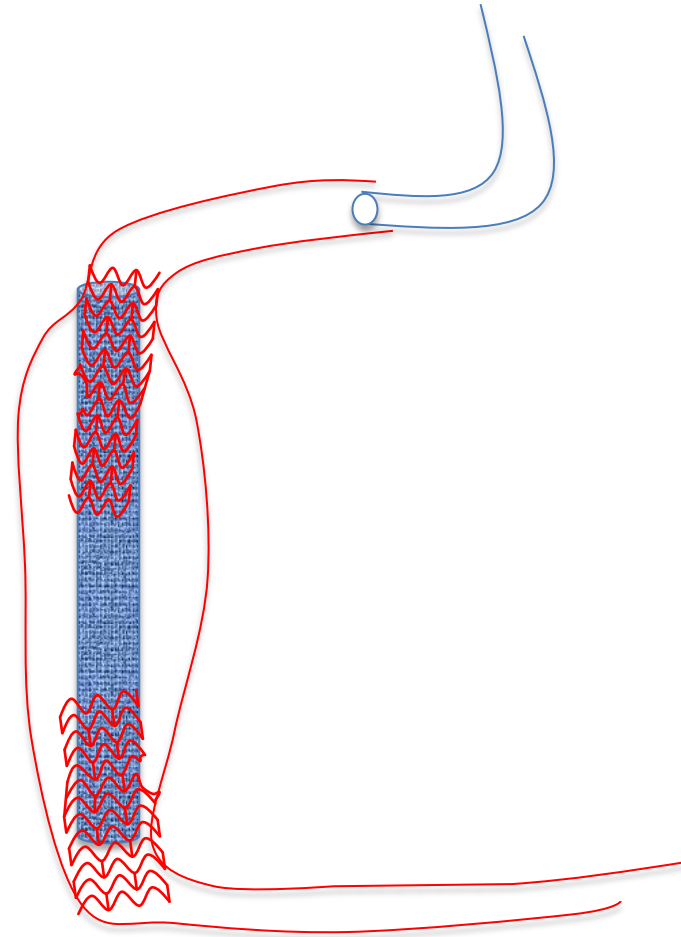
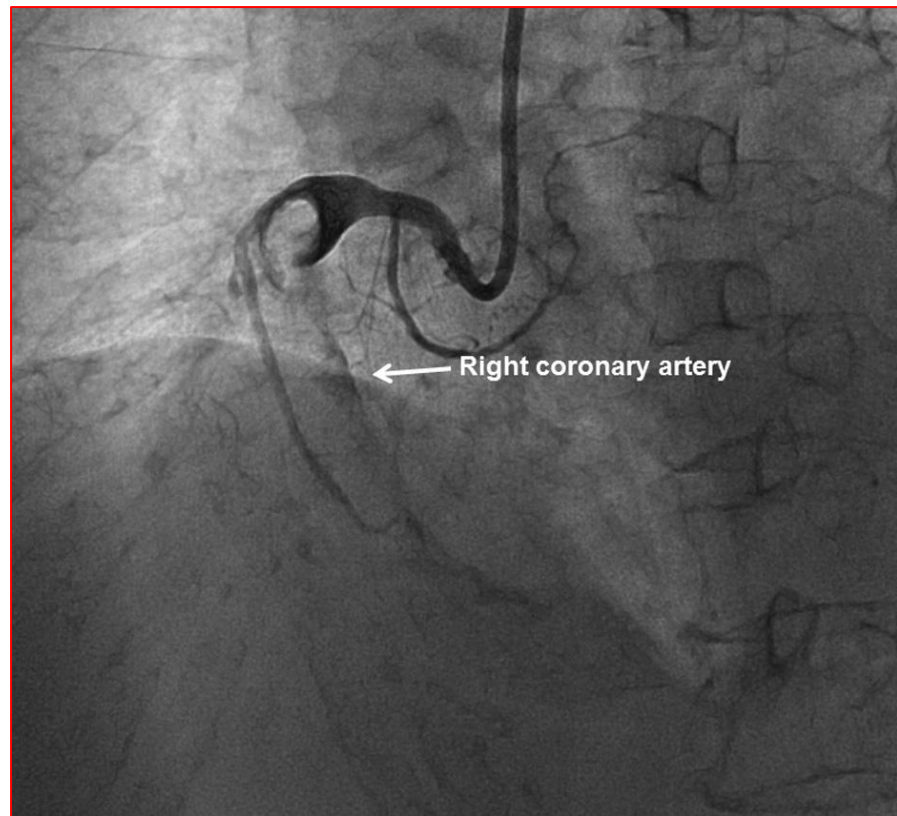
Suivi à 3 mois



Suivi à 3 mois



Technique: Tunnel pour géant



Kobayashi, Y., et al. (2014). "Acute myocardial infarction after Kawasaki disease." JACC Cardiovasc Interv 7(7): e77-78.

Message pour la maison

Garder son calme, rester concentrer

