

# DÉCLARATION DE LIENS D'INTÉRÊT AVEC LA PRÉSENTATION

**Intervenant : Maxime TAPPONNIER, Sion**

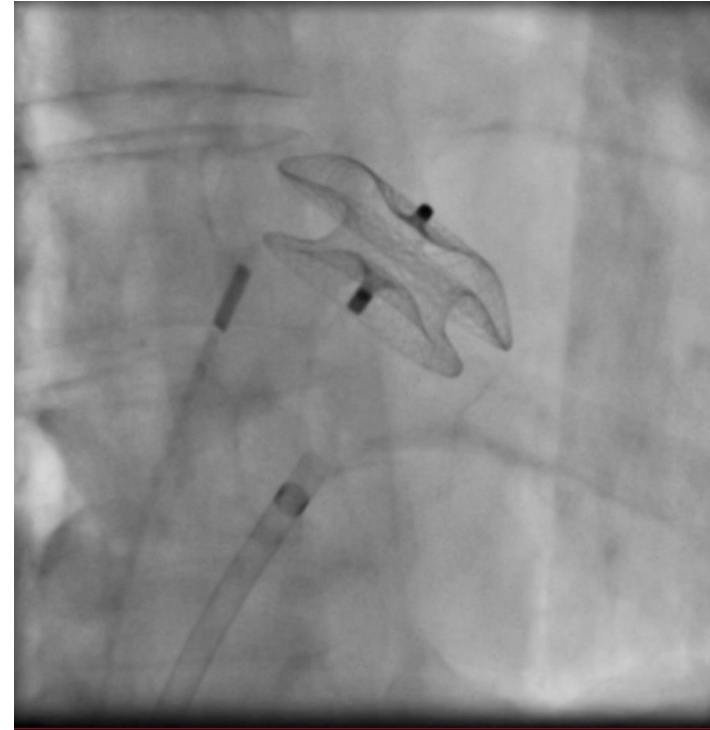Je n'ai pas de lien d'intérêt à déclarer

# Leçon de modestie

Dr Maxime Tapponnier  
Cardiology department  
Sion & CHUV Hospital  
Switzerland

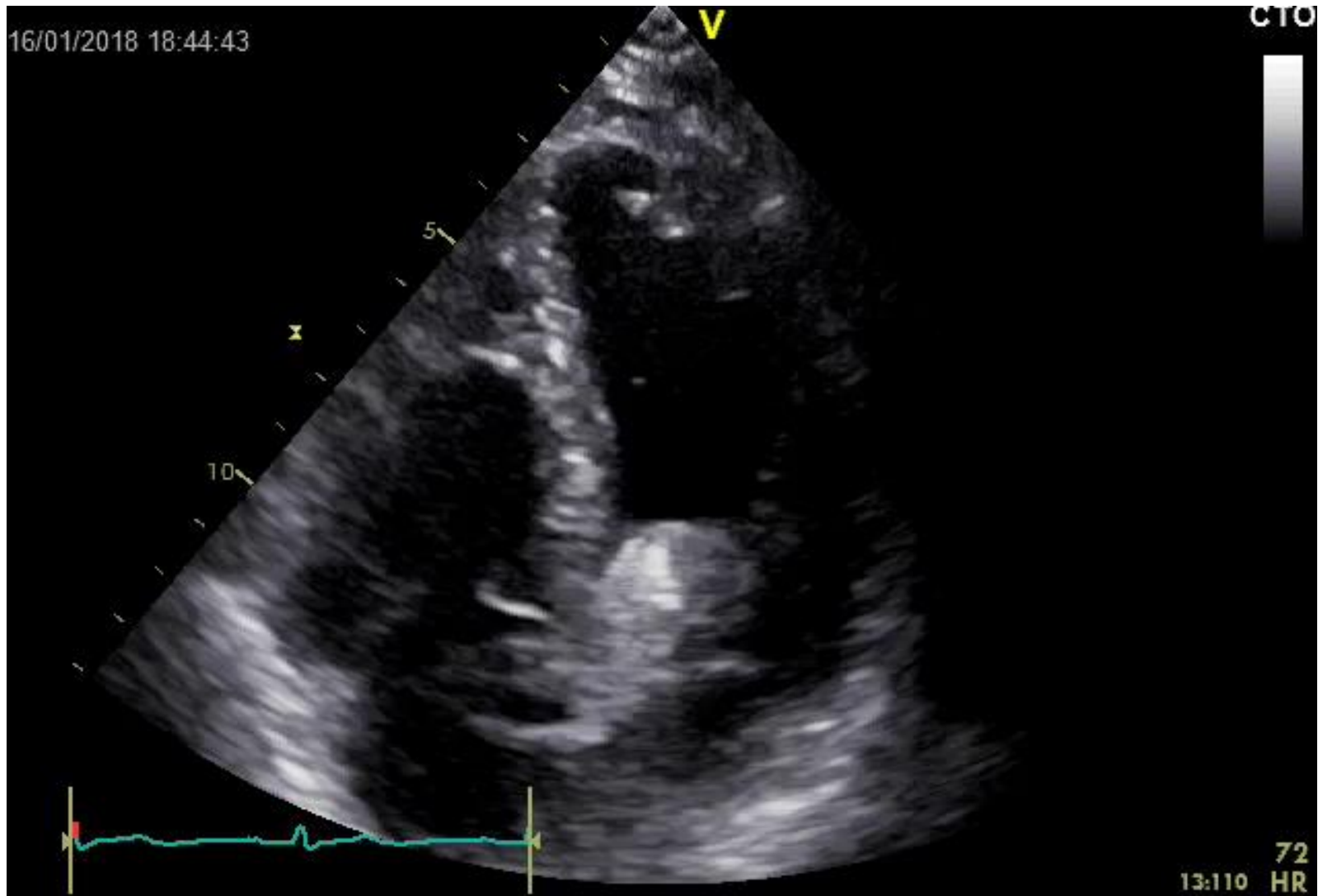
# Clinical history

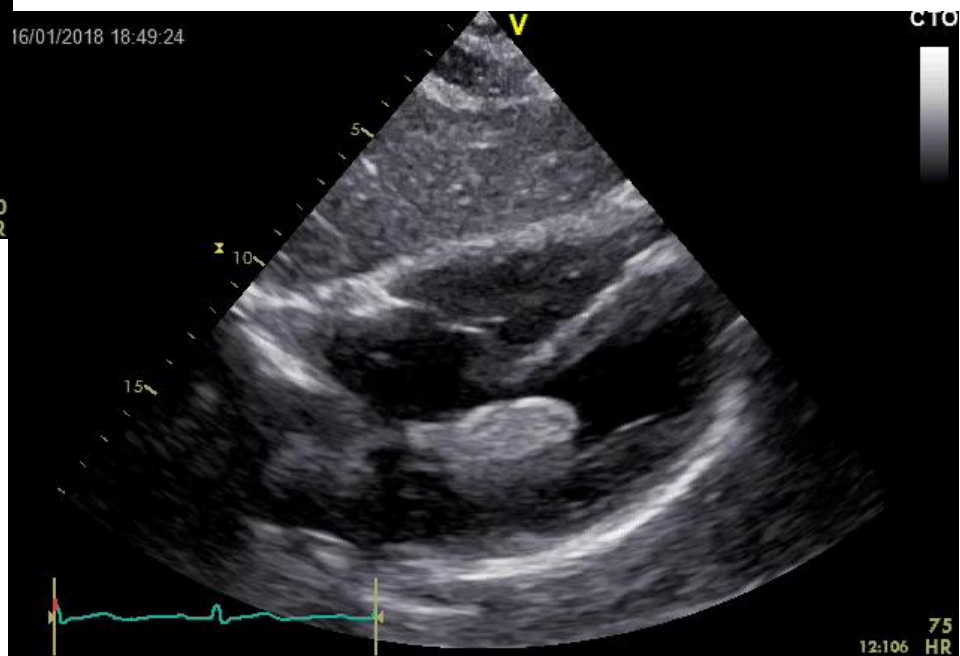
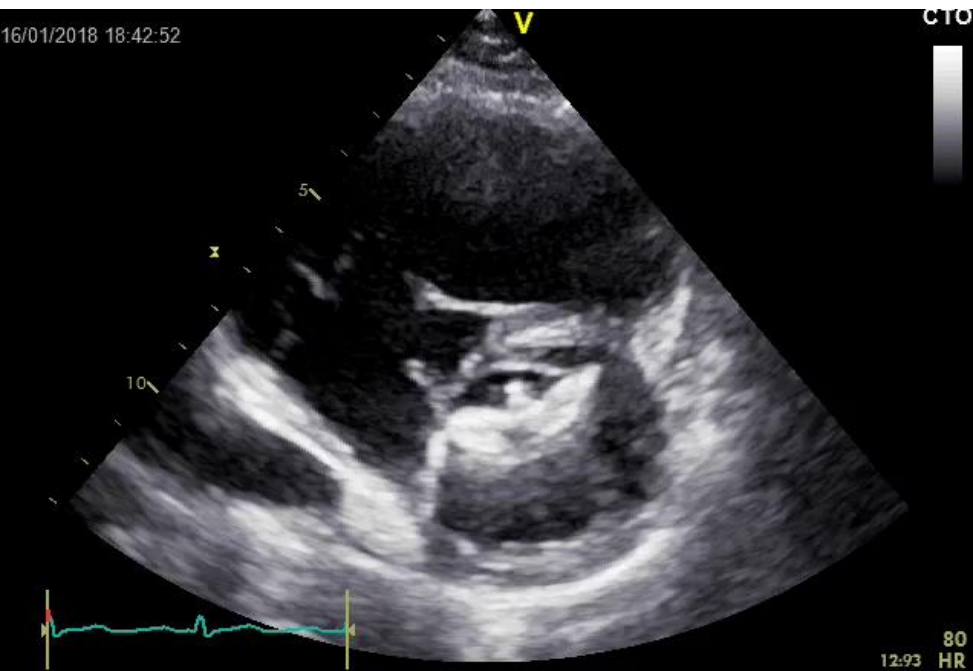
- 58 year-old Swiss lady
- Closure of an ASD in September 2017 (Amplatzer Septal Occluder 18 St Jude) (Cantonal hospital of Sion, Valais)
- «Routine procedure», under local anesthesia, intracardiac echo
- Result considered ok, follow-up at 3 months



# Clinical history

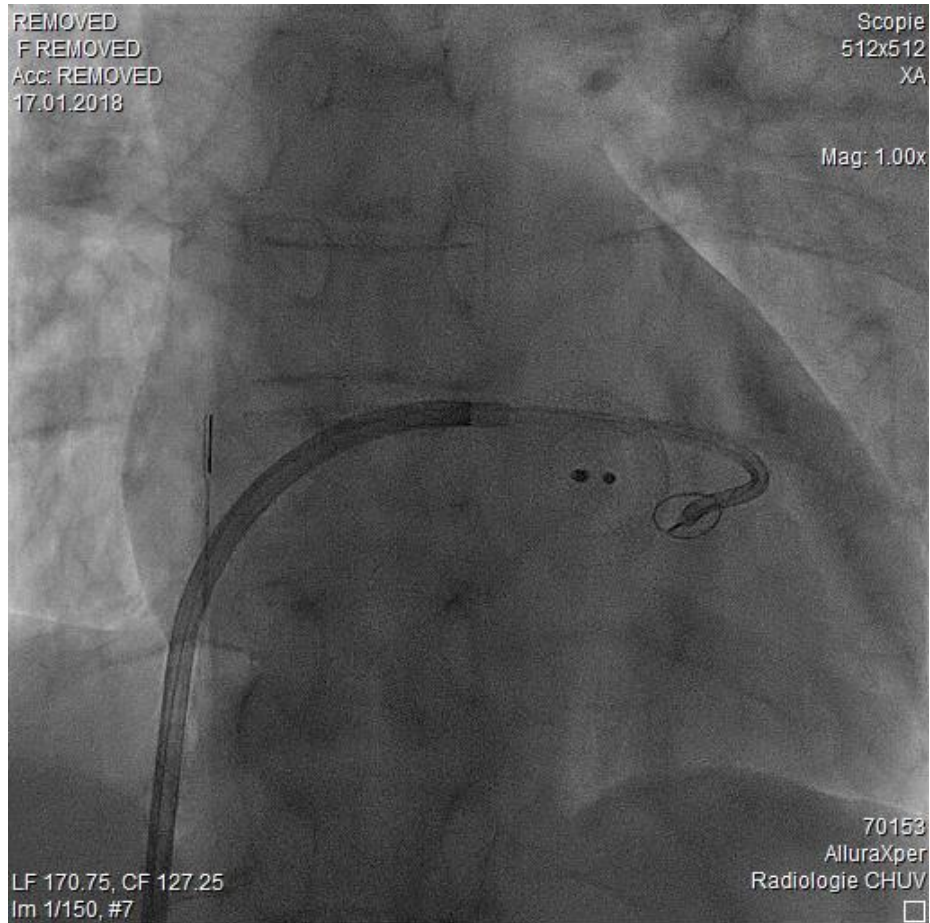
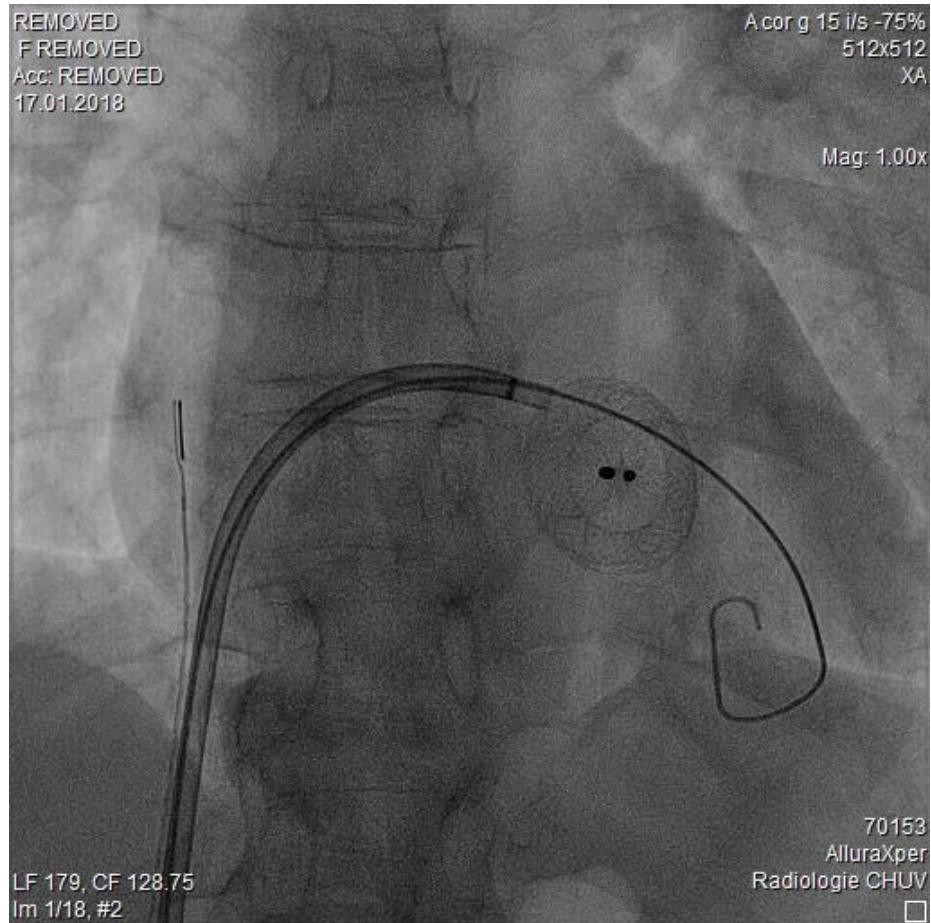
- Control echo 3 months later by referring cardiologist (mid January 2018)
- Progressive mild shortness of breath
- Some palpitations





# What to do??

- Gentle attempt, surgical back-up
- Conscious sedation
- Intracardiac echo
- Try to snare from venous side





REMOVED  
F REMOVED  
Acc: REMOVED  
17.01.2018

Scopie  
512x512  
XA

Mag: 1.00x

LF 170.75, CF 127.25  
Im 1/150, #12

70153  
AlluraXper  
Radiologie CHUV



REMOVED  
F REMOVED  
Acc: REMOVED  
17.01.2018

Scopie  
512x512  
XA

Mag: 1.00x

LF 170.75, CF 127.25  
Im 1/150, #13

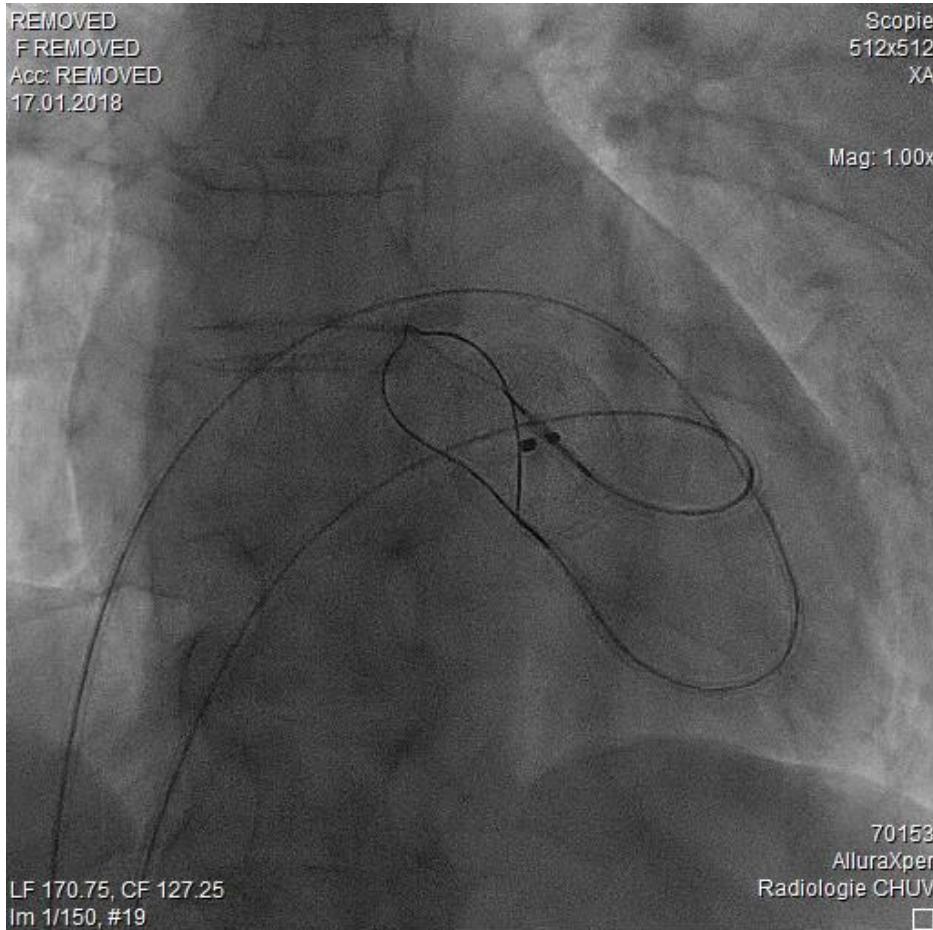
70153  
AlluraXper  
Radiologie CHUV



REMOVED  
F REMOVED  
Acc: REMOVED  
17.01.2018

Scopie  
512x512  
XA

Mag: 1.00x



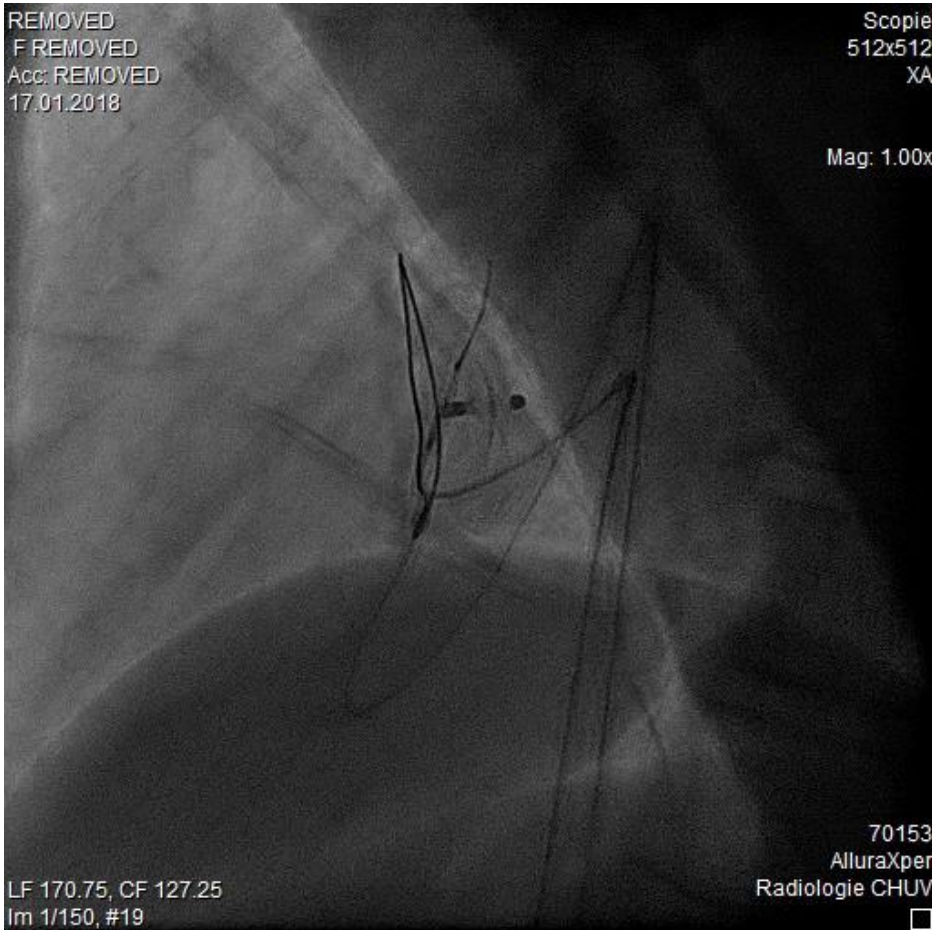
LF 170.75, CF 127.25  
Im 1/150, #19

70153  
AlluraXper  
Radiologie CHUV

REMOVED  
F REMOVED  
Acc: REMOVED  
17.01.2018

Scopie  
512x512  
XA

Mag: 1.00x

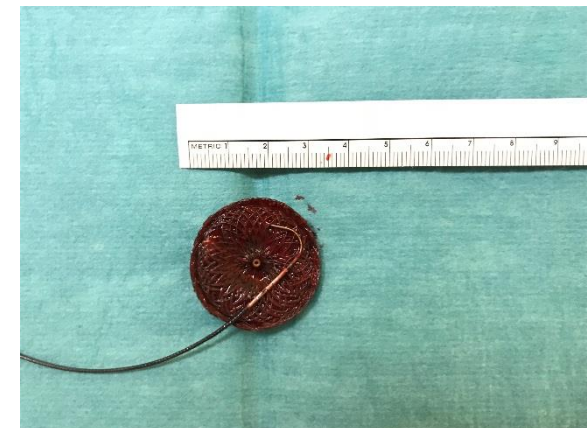

LF 170.75, CF 127.25  
Im 1/150, #19

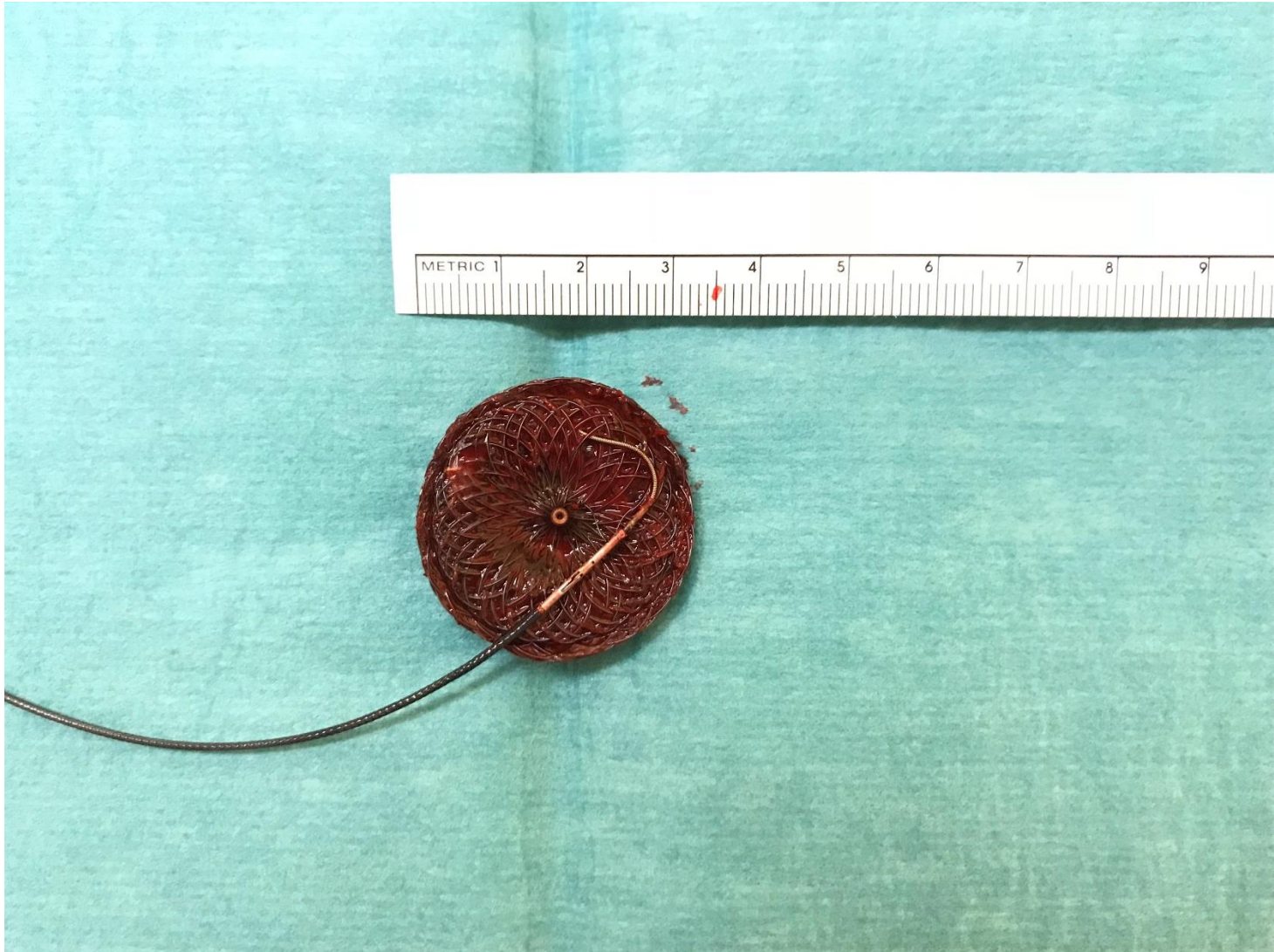
70153  
AlluraXper  
Radiologie CHUV

# So what happened...

- Sudden hypotension
- Massive tamponade – very active bleeding
- Forceps catheter stuck in the Septal Occluder device...
- Autotransfusion of abt 3l of blood...
- Bleeding finally stopped & taken to OR for devices retrieval & surgical correction of the ASD
  
- Surgeon... really unhappy
- Luckily took them only 45 minutes...



# Greetings from your best friend the cardiac

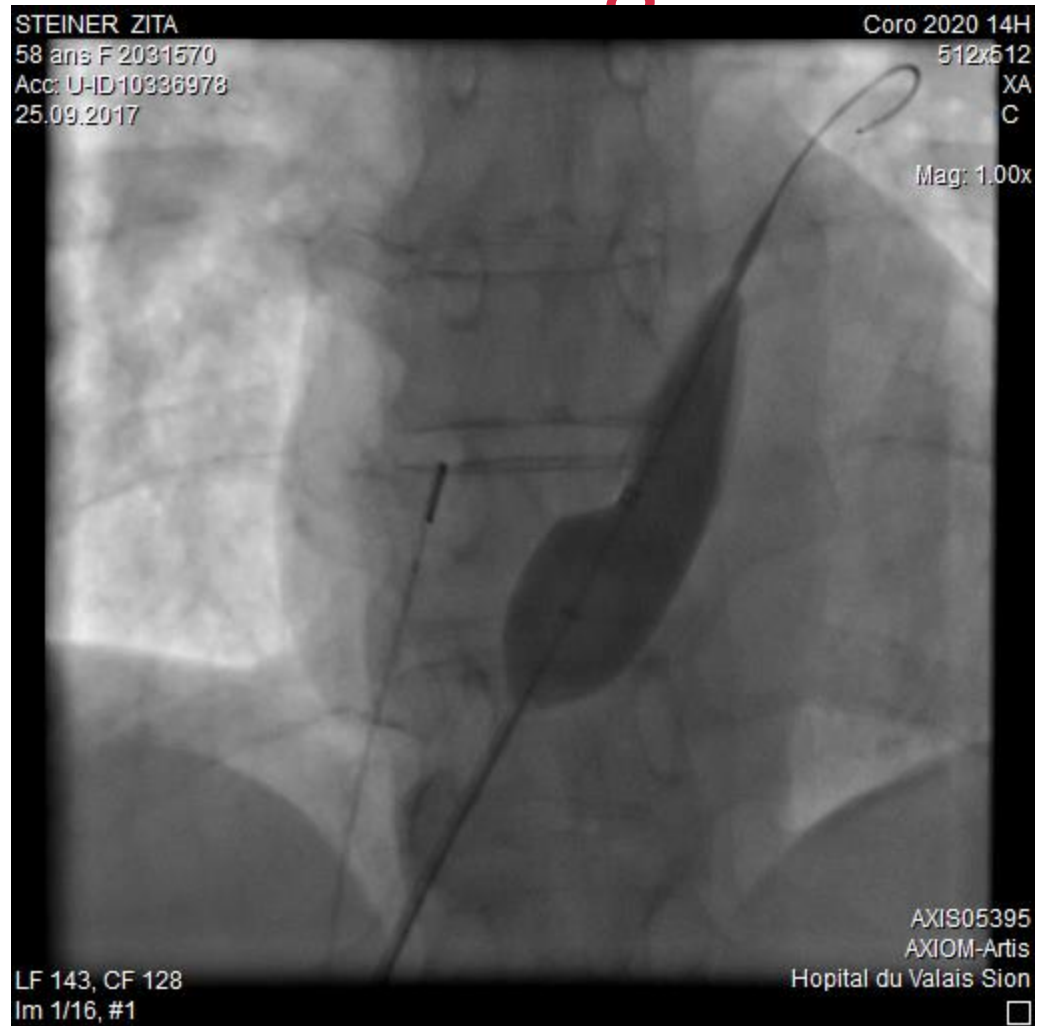


# So what did we learn

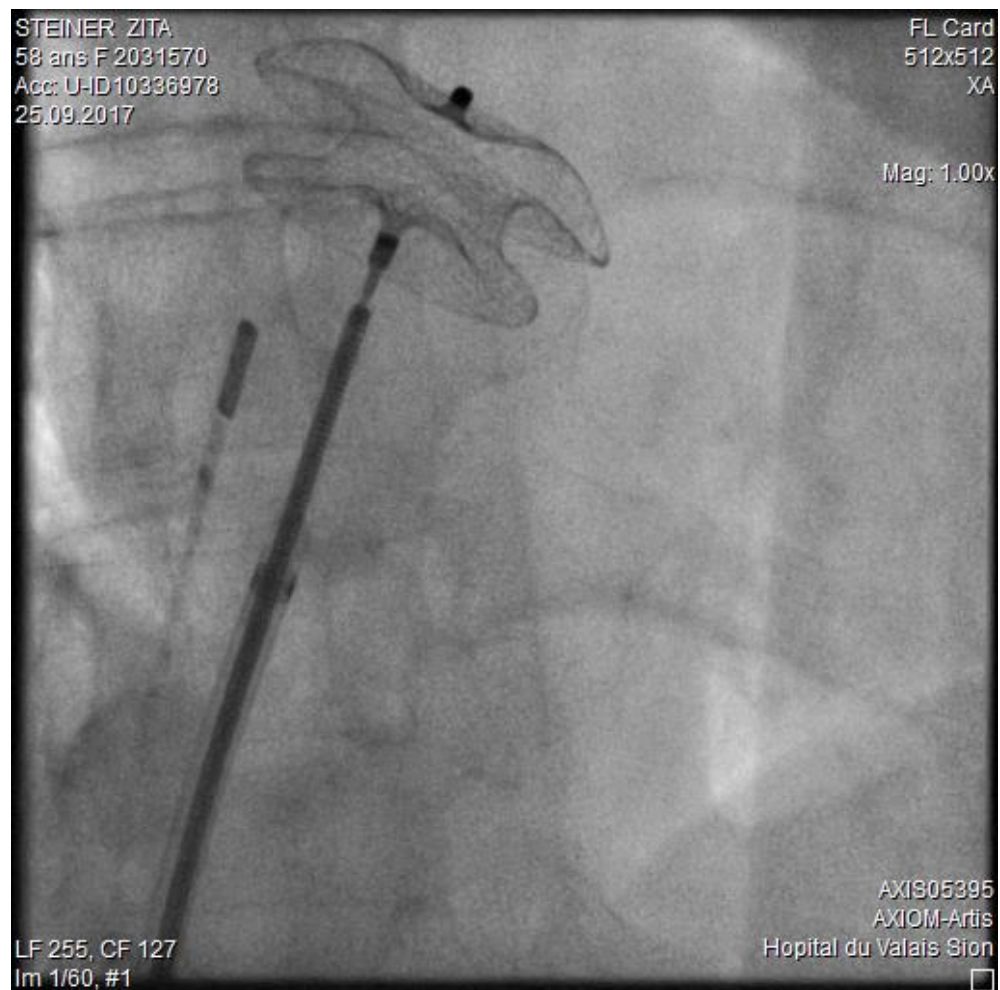
- Remain modest, interventional cardiologists should realize that they can't do all
- We did fail here, luckily the clinical outcome was good

Merci de votre attention

# Sizing

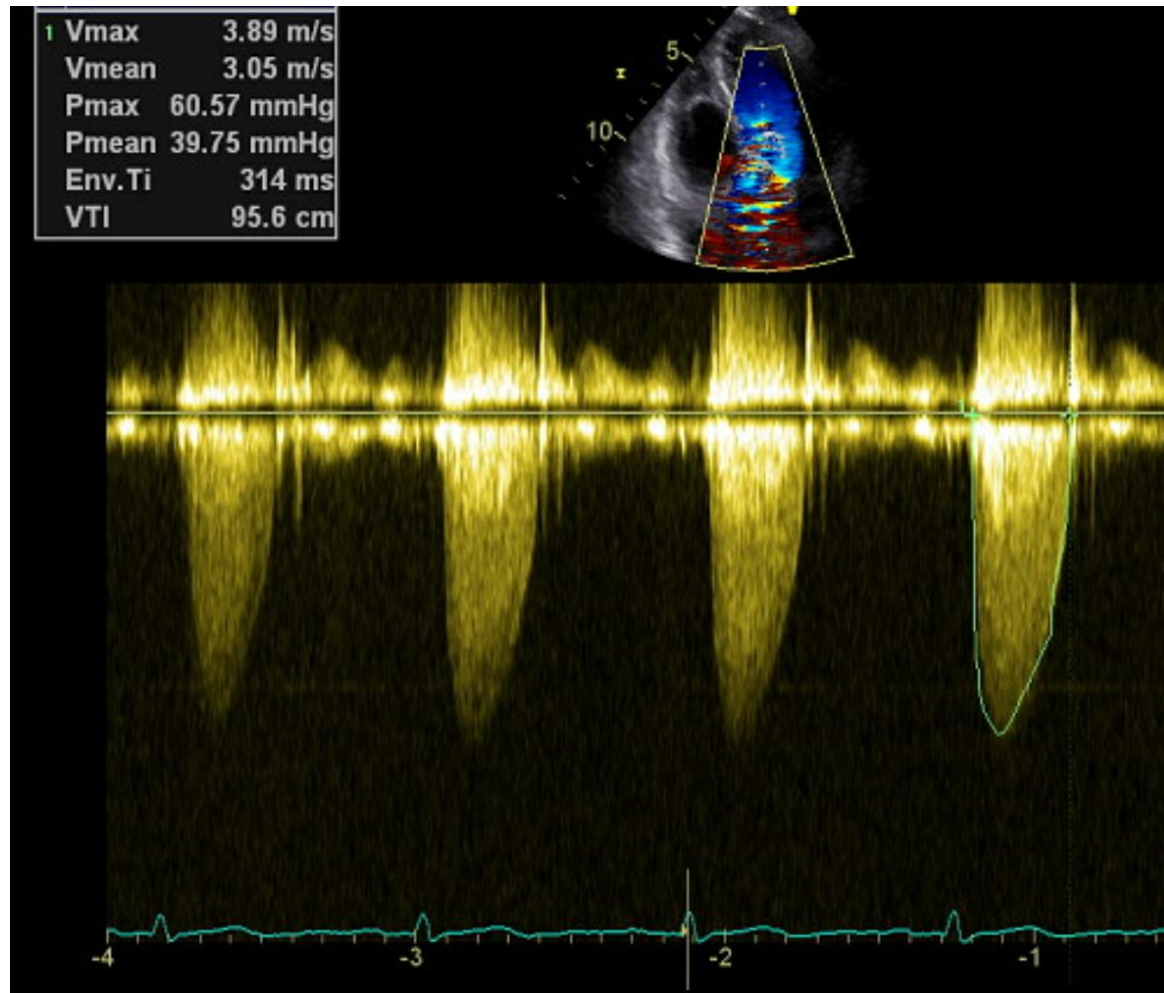


# Procedure



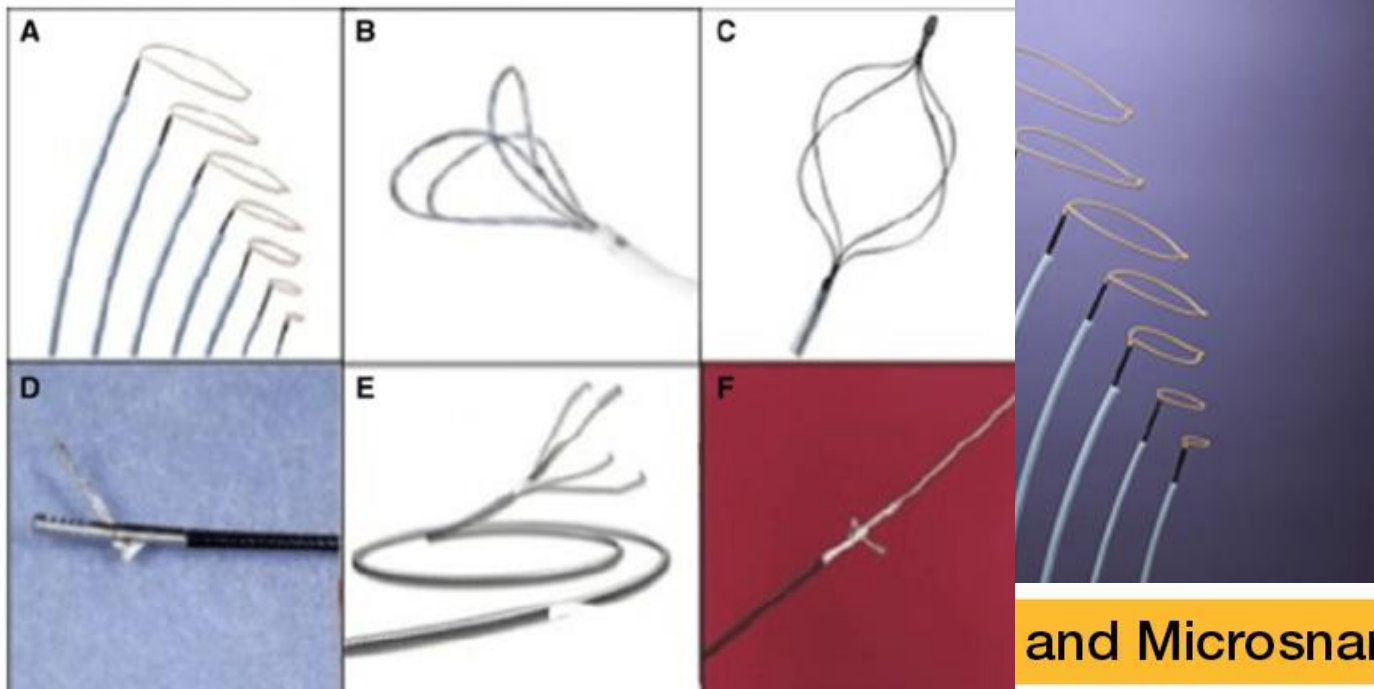


# ETT



# Capture devices & Goose Neck

**Fig. 2** There are a range of purpose-designed devices now available. **A** Amplatz gooseneck snare (ev3). **B** Trefoil En-Snare (Merit Medical). **C** Dormia baskets. **D, E** Alligator retrieval forceps (Cook Medical and ev3). **F** Myocardial biopsy forceps (Cook)



and Microsnare

## Amplatz GooseNeck® Snare Kit (kit includes Snare, Snare Catheter)

Model No.	Loop Diameter (mm)	Snare Length (cm)	Catheter Size (F)	Catheter Length (cm)
GN500	5	120	4	102
GN1000	10	120	4	102
GN1500	15	120	6	102
GN2000	20	120	6	102
GN2500	25	120	6	102
GN3000	30	120	6	102
GN3500	35	120	6	102

# Retrieval Forceps Aligator



## VASCULAR RETRIEVAL FORCEPS

- The low-profile device can be delivered through a catheter with an ID larger than .045 inches and inserted through a hemostasis valve.
- The device features a PTFE-sheathed, braided stainless steel shaft and strong gripping jaws.
- The distal spring-coil tip is designed to prevent you from inadvertently engaging the vascular wall during manipulations.

Order Number	Reference Part Number	Fr	Length cm
G07187	VRF-3.0-120	3	120

Some products or part numbers may not be available in all markets. Contact your local Cook representative or Customer Service for details.

